

Bipartite parietal bone: a case from Croatian population

Jerković, Ivan; Dolić, Krešimir; Skejić, Ivan; Mladenović, Saša; Jerković, Nika; Bareša, Tina; Kružić, Ivana; Bašić, Željana

Source / Izvornik: **Journal of bioanthropology, 2022, 2, 14 - 21**

Journal article, Published version

Rad u časopisu, Objavljena verzija rada (izdavačev PDF)

<https://doi.org/10.54062/jb.2.1.4>

Permanent link / Trajna poveznica: <https://urn.nsk.hr/urn:nbn:hr:227:985031>

Rights / Prava: [Attribution 4.0 International](#)/[Imenovanje 4.0 međunarodna](#)

Download date / Datum preuzimanja: **2025-01-10**

SVEUČILIŠTE
U
SPLITU



SVEUČILIŠNI
ODJEL ZA
FORENZIČNE
ZNANOSTI

Repository / Repozitorij:

[Repository of University Department for Forensic Sciences](#)



UNIVERSITY OF SPLIT


dabar
DIGITALNI AKADEMSKI ARHIVI I REPOZITORIJI

Bipartite parietal bone: a case from Croatian population

Željana Bašić¹, Ivan Jerković^{1*}, Tina Bareša¹, Nika Jerković², Saša Mladenović², Ivan Skejić³, Krešimir Dolić³, Ivana Kružić¹

¹University of Split, University Department of Forensic Sciences, Ruđera Boškovića 33, 21000 Split

²University of Split, Faculty of Science, Ruđera Boškovića 33, 21000 Split

³University Hospital Center Split, Clinical Department for Diagnostic and Intervention Radiology, Spinčićeva 1, 21000 Split

* Corresponding author: Email: ivanjerkovic13@gmail.com

Received July 21st, 2022

Accepted for publication October 17th, 2022

Online First October 27th, 2022

Keywords: cranial variation, epigenetic traits, bipartite parietal bone, MSCT, Croatia.

Abstract

This study reports the first case of the bipartite parietal bone in the Croatian modern and archaeological population. We have examined 458 skulls from Multi-Slice Computed Tomography (MSCT) images and found only one case of this trait (0.22%; 95%CI 0.01%-1.21%). The bone exhibiting an additional suture was the left parietal; the type of the trait was complete, horizontal, and asymmetrical. Some additional sutural bones were observed, including asterion and lambda ossicle and two lambdoid ossicles. Among the other epigenetic variants, parietal, zygo-facial, oval, and mastoid foramina, frontal grooves, supratrochlear notch, and condylar canal were visible. The principal components analysis (PCA) of features extracted from the frontal, lateral, and posterior view of 110 female crania using a convolutional neural network (CNN) for image analysis demonstrated that the skull deviated from the average female skull in the population. The visual and metric examination of the skull showed ultrabrachycephaly, mild lateral deformational plagiocephaly, and depression on the posterior part of the skull.

The rarity of this case in the Croatian population indicated that this variant could be interesting for both clinicians and forensic anthropologists, as it can be used as means of comparative identification. Further studies will show its importance in assessing population affinities and relations inside the graveyards.

Introduction

Bipartite parietal bone (divided parietal bone, double parietal bone, or sutura parietalis) is one of the variants in mammalian skulls, which is more frequent in other mammals than in humans (Shapiro, 1972). According to Hrdlička, the first mention of the bipartite bone occurred in 1753 by Tarin (Hrdlička, 1903), but its etiology has not been clarified to date. Some authors consider that it occurs due to several (usually two) ossification centers (Bhatt, Hunsaker, & Kalina, 2014; Goss, 1954; Hauser & De Stefano, 1989; Sanchez, Stewart, Walvick, & Swischuk, 2010), while others

believe that it develops from one (Gray, 1901; Shapiro, 1972). This variant can be extremely important when analyzing human skeletal remains in a forensic and archaeological context, especially in children, where it can be mistaken for trauma (especially when unilateral) when analyzing head X-rays. This is more pronounced in children because in adults sclerosis or sutural seriation can be good indicators of the absence of trauma (Shapiro, 1972). On the other hand, considering its frequency, it could be one of the individual traits used for analyzing unidentified human remains when comparative identification is possible.

There are several types of expression of the trait, which include: complete horizontal (symmetrical and asymmetrical), complete vertical (symmetrical and asymmetrical), and incomplete form (Shapiro, 1972). In some cases, it can be tripartite or even quadripartite, as published by Fusari, Maggi and Rannke and discussed by Shapiro (Shapiro, 1972). Additionally, Hauser and De Stefano suggest that divided parietal bone has to be recorded by the completeness of division (complete; partial – if longer than 1 cm; trace – if less than 1cm long), by direction (horizontal, vertical, or oblique), and by the number of parts (two, three, four) (Hauser & De Stefano, 1989).

This variance can be accompanied by skull asymmetry, hydrocephalus, plagiocephaly, additional sutures (os suturarum, metopic suture, mastoid suture, sutura mendosa) as well as the obliteration of some other sutures and the teeth retention (Abdel-Salam et al., 2014; Becker, Cheverud, Govier, & Kane, 2005; Berry, 1909; Bessell-Browne & Thonell, 2004; Fenton, Sirotnak, & Handler, 2000; Hauser & De Stefano, 1989; Hrdlička, 1903; Shapiro, 1972).

The frequency of bipartite parietal bone in studied populations is low; for example, Hauser and De Stefano estimate that its frequency is less than 1% (Hauser & De Stefano, 1989). In his clinical experience, Shapiro estimated that this trait was extremely rare (3 of around 25,000 examined RTG images), which was additionally supported by Hrdlička, who found 8 cases of parietale bipartita in the sample of 34,000 humans (Shapiro, 1972). Almeida Prado et al. have done an extensive literature review and found three cases in 711 skulls; and 80 cases reported in previously published literature from 1753 to 2016 (Hrdlička, 1903; Prado et al., 2016).

To our knowledge, our paper is first to present the finding of the bipartite parietal bone in the sample of the Croatian population.

Materials and methods

Settings

The Multi-Slice Computed Tomography (MSCT) images of crania were obtained at the Department of

Diagnostic and Interventional Radiology of the University Hospital Center Split (Croatia) using device Definition Edge (Siemens AG Medical Solutions, Erlangen, Germany) with a slice thickness of 0.75 mm. The soft tissue convolution kernel and original slice thickness were used for image reconstruction.

Crania were examined using OsiriX MD 12.5 (Pixmeo SARL, Geneva, Swiss 2021) in 2D views and 3D volume rendering techniques (VRT). Visualizations were provided using 3D Cinematic Rendering mode.

Anatomical analysis

The epigenetic variants of the crania were analyzed according to Hauser and De Stefano (Hauser & De Stefano, 1989). The skull was measured, and cranial vault asymmetry index (CVAI) (Callejas Pastor et al., 2020), skull shape (Langley, Jantz, Ousley, Jantz, & Milner, 2016; Looman & Flannery, 2012; Topinard, 1885), and transcranial diameter difference (TDD) were calculated (Looman & Flannery, 2012).

Image analysis and Principal components analysis

MSCT database consisted of 274 skull scans from University Hospital Split (137 females and 137 males), age of females ranging from 18 to 93, and males from 18 to 88. Only patients without head trauma and other anomalies that could affect the skull size and morphology are included into the collection. We used 110 female crania with visible region of interest from our MSCT database to compare our patient to the other female patients without the described condition. As we did not have population osteometric or landmark data for comparison, we captured in 3D VRT three images of each cranium in frontal, lateral, and posterior views and conducted image analysis.

Classic computer graphics-based methods rely on per-pixel-based multi-scale feature computation, resulting in complex and timely modeling. To address the complex and timely modeling, we used a convolutional neural network (CNN) for image analysis. We employed the transfer learning approach, which also can be used for image classification when dealing with restricted sample sizes (Shaha and Pawar, 2018), to represent

images as arrays of numerical values, each describing a specific extracted feature.

Images were imported into Orange Data Mining, version 3.32.0, a visual programming tool for quick prototyping (Demšar et al., 2013). Among different CNN architectures commonly used for image analysis, we selected VGG16, a CNN model for image feature extraction. VGG16 model achieves a 92.7% top-5 test accuracy on the ImageNet dataset. Furthermore, the network has 16 layers and multiple 3X3 kernel-sized filters resulting in increased depth of the neural network facilitating the understanding and recognition of more complex features and patterns (Simonyan & Zisserman, 2015). As the feature extractor provided 4096 features for each cranial image, we used principal component analysis (PCA) to reduce the dimension of the data and reveal where the cranium with bipartite parietal will cluster within other female crania sample.

Ethical declarations: Approved by the ethical committees of the University Hospital Centre Zagreb (Class: 8.1-21/216-3; Number: 02/21 AG.), University Hospital Centre Split (Class: 500-03/17-01/56; Number: 2181-147-01/06/M.S.-17-2), and University Department of Forensic Sciences (Class: 024-04/17-03/00026; Number: 2181-227-05-12-17-0003).

Results and Discussion

The patient in whom we found a unilateral bipartite parietal bone was a female, age 55. She was admitted to the emergency room due to strong headaches and vertigo. Brain MSCT was administered, but no acute focal changes were found.

The skull length was 159.9 mm, and breadth 149.5 mm, producing a cranial index of 93.5, which defines the skull as ultrabrachycephalic (extremely wide and short). There was central posterior deformity and widening of the posterior skull characteristic of posterior deformational plagiocephaly. CVAI was 3.25, which did not indicate plagiocephaly. However, the skull exhibited fronto-lateral differences between the left and right side, with visible bulging on the right side of the occipital bone (Figure 1). TDD was 5.5 mm, implying the lateral deformational plagiocephaly of mild severity (flattening restricted to the back of the skull).

The left parietal bone was bipartite and unfused; the type was complete, horizontal, and asymmetrical. It was located at the first third closest to the squamous suture/border of the parietal bone starting at the lambdoid suture, 2.98 cm from asterion and 3.20 cm from pterion (Figure 2).

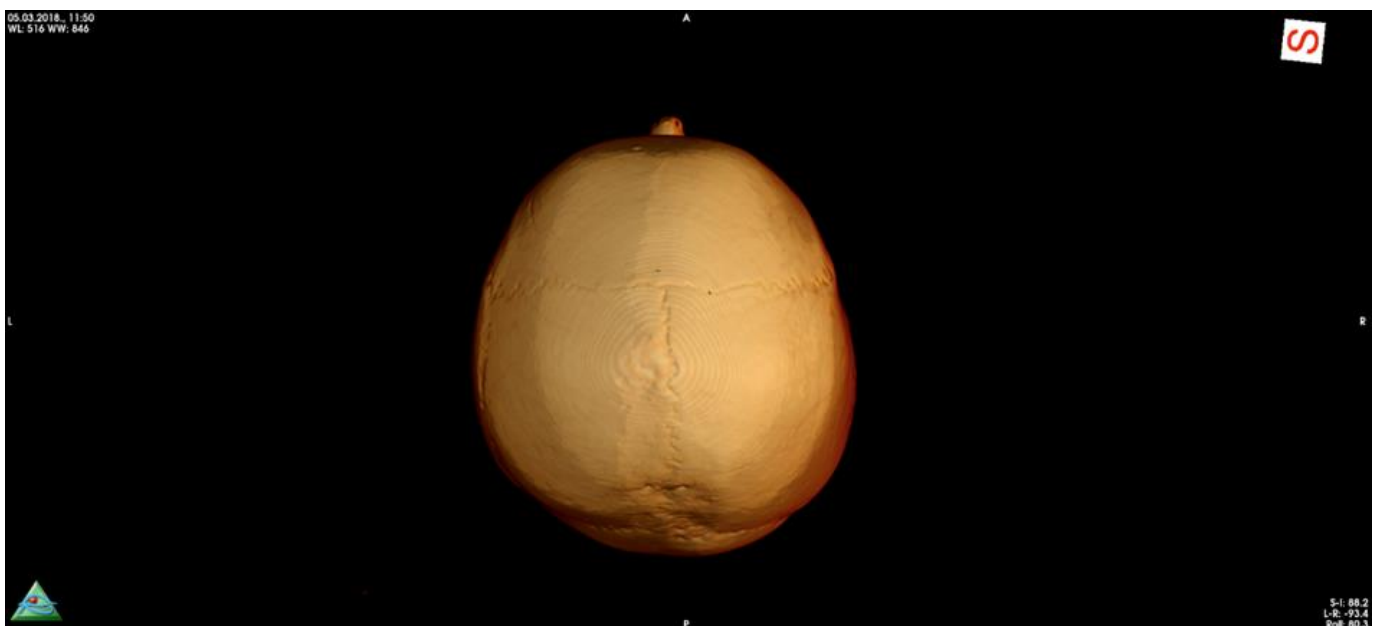


Figure 1. Superior view of the skull indicating occipital bulging on the right side and unsymmetrically positioned sagittal suture.

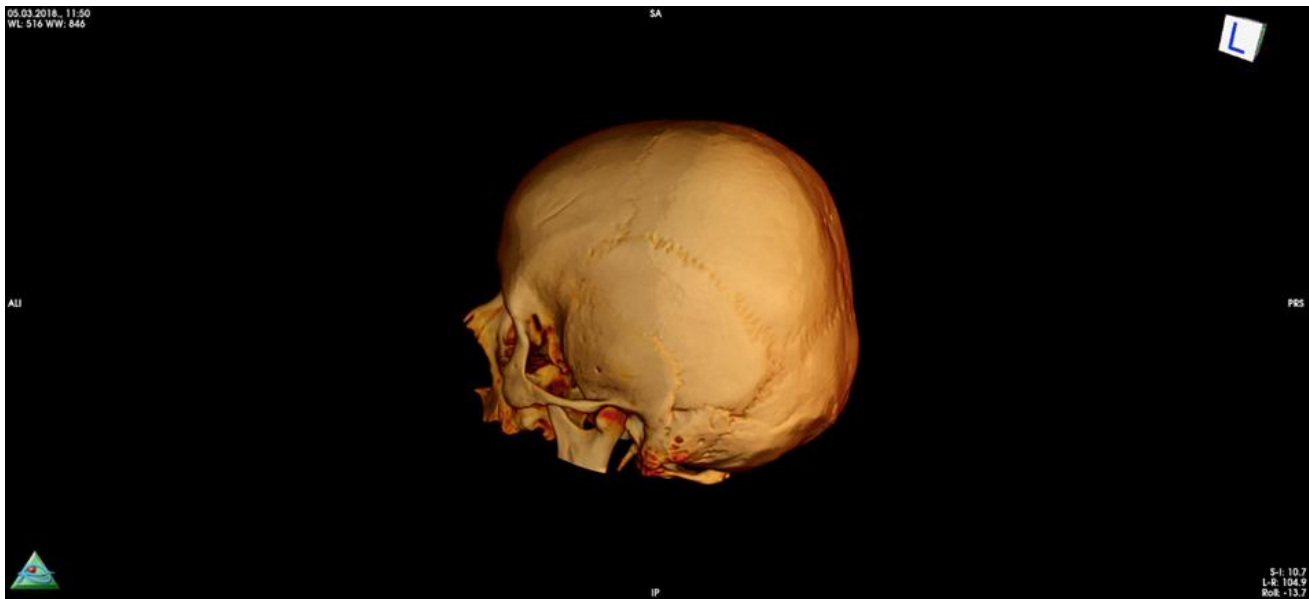

Figure 2. Lateral view of the skull showing the position of the additional suture and pronounced occipital flattening.

The sagittal suture was shifted slightly right from the midsagittal plane (Figure 1). The depression was visible on the posterior part of the skull, in the area from the posterior half of the sagittal suture to the external occipital protuberance, concentrating on the area around the midline (Figure 3). Mild, unsymmetrical flattening of the entire occiput was visible (Figure 2). The other sutures showed no asymmetrical closures or pathological obliterations.

An asterion ossicle was visible on the left side. There was a lambda ossicle and two lambdoid ossicles, one on the right side of the junction with the additional sagittal suture and the other on the right side of the lambda (Figure 4). Among other variants of human skull, we identified bilaterally: parietal foramen, frontal groove, supratrochlear notch, mastoid foramen, and foramen ovale. Four zygofacial foramina, one on the left and three on the right bone, were also visible. The condylar canal was visible on the left side.

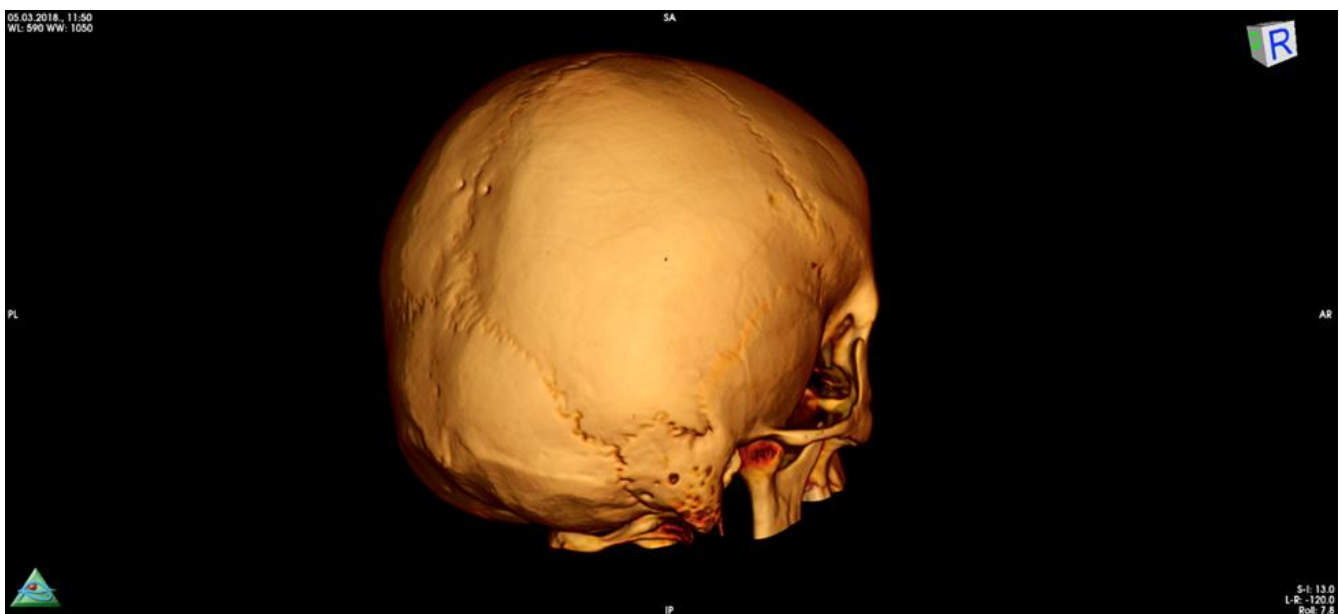


Figure 3. Lateroposterior view showing the depression on the posterior part of the skull.

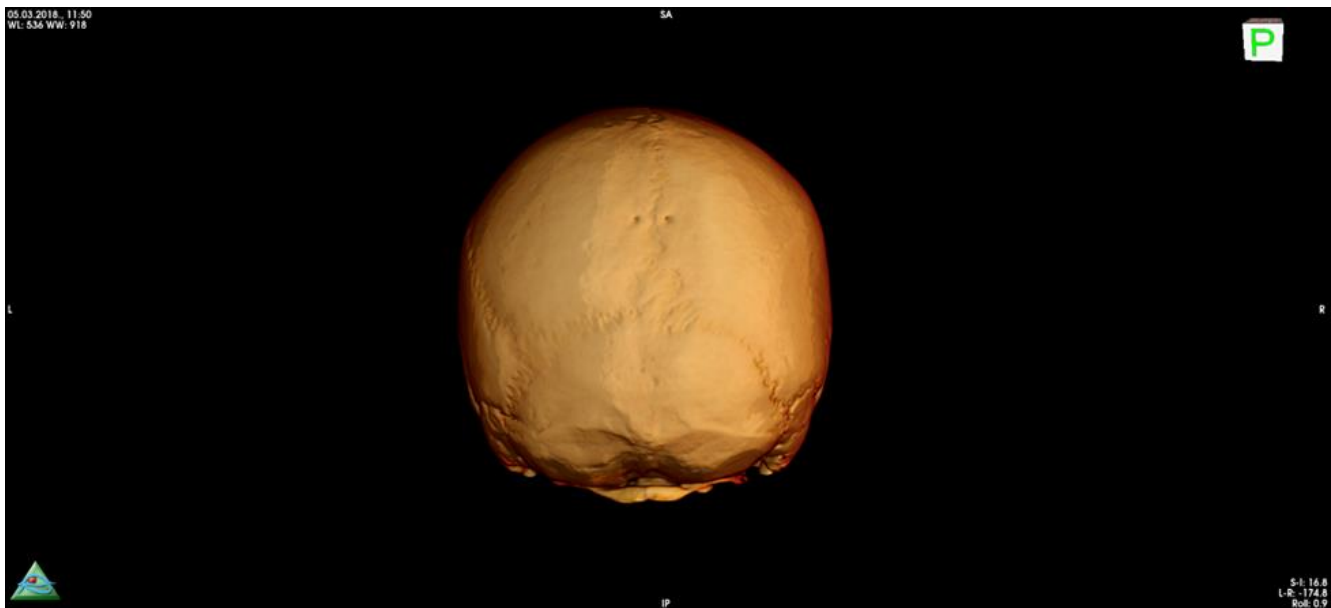


Figure 4. Posterior view of the skull showing the additional ossicles.

Among unrelated findings, we identified, a button osteoma was visible on the left part of the frontal bone and deviated nasal septum.

The depicted case was the only case of bipartite parietale in the virtual collection of 458 skull MSCTs, so the frequency of this trait in the examined population was 0.22% (95%CI 0.01%-1.21%).

To analyze this specific skull within the referent population, features obtained by image analysis (of frontal, lateral, and posterior views) were transformed using the first two principal components that explained the highest amount of variance. The first two components explained 25% of the variance in frontal, 21% in lateral, and 30% in posterior view. While in lateral view examined skull did not remarkably deviate from the rest of the sample, in frontal and posterior views, the skull was positioned at the edges of the quadrants (Figure 5).

Discussion and Conclusion

Our literature search found no similar case in the Croatian population, making this the first reported case of bipartite parietal bone in the Croatian population from both modern and archaeological settings. This is one of the less-represented studies that report findings

at the population level, which is essential for studying such low-frequency anatomical traits. The low frequency of this trait in the examined population suggests that the trait could have identification weight, and it could be important for comparative identification purposes in forensic context when antemortem images are available. This finding could also be of value in clinical forensic medicine and expert opinion report when it could possibly be mistaken for a skull fracture in a case of suspected head trauma.

On the population level, this person's cranium was one of the 458 MSCT cranial images examined through this project, suggesting the trait prevalence of 0.22%. This frequency should be taken with caution considering the sample size and previous studies that showed much lower frequency ranging from 0.012% (Shapiro, 1972) to 0.024% (Hrdlička, 1903). The most recent study reported a frequency of 1.94% in the population of Cyprus, while the total sample of four examined countries (including Cyprus) was 0.42%. However, if this sample was divided by population, that would indicate that Brazil, Portugal, and Greece had no cases of this trait (Prado et al., 2016). Interestingly, the highest frequency of this trait was observed in samples from modern Croatian and Cypriot populations, which are geographically not distant. Population frequency in other European or Mediterranean populations is still

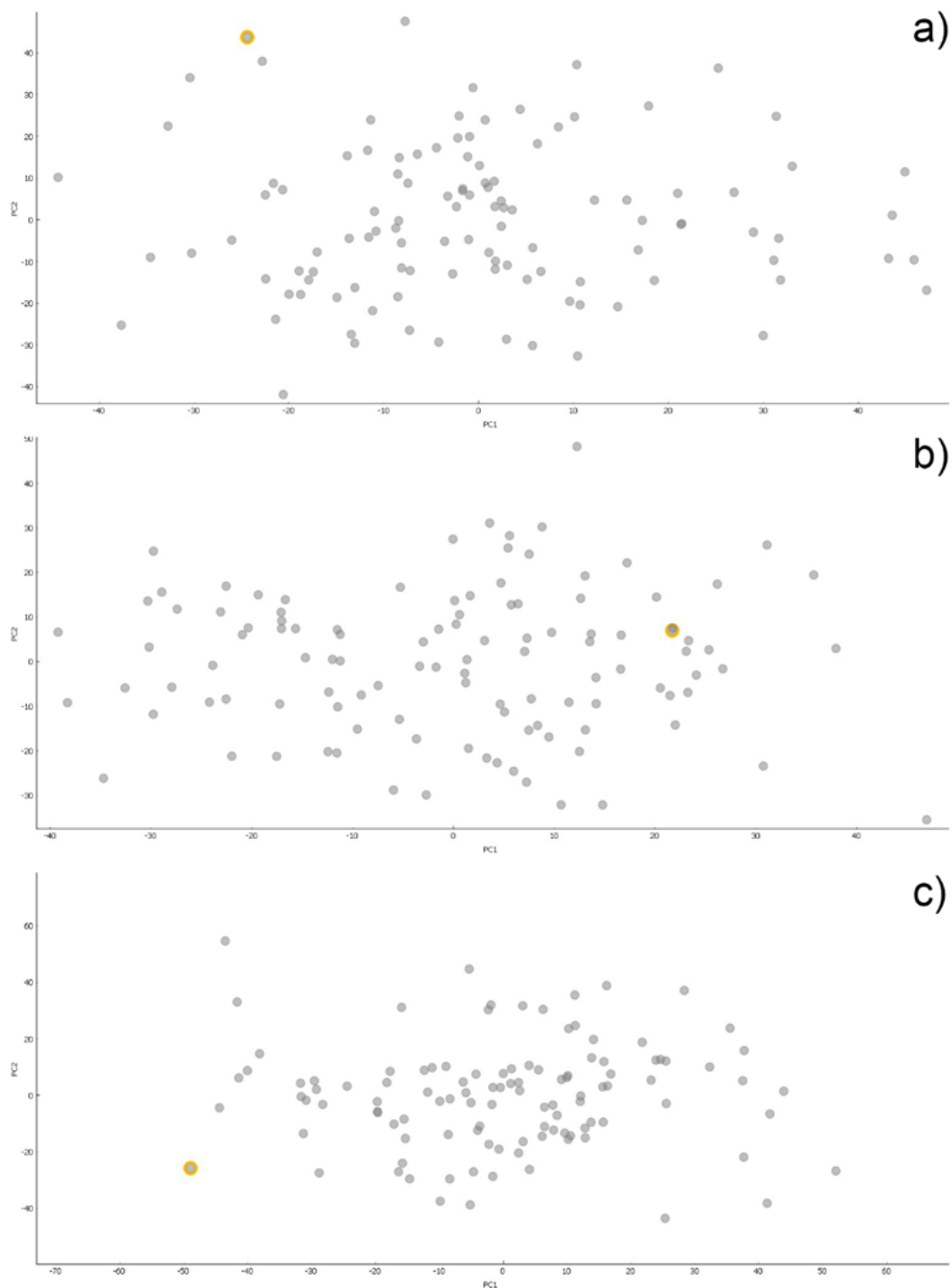


Figure 5. PCA analysis of frontal (a), lateral (b), and posterior (c) view of crania indicating position of the skull with divided parietal bone within referent population of female crania (n=110).

unknown as this trait is mainly found in case reports in clinical or medico-legal contexts, usually concerning infants and discussing clinical implications (Abdel-Salam et al., 2014; Angonese, Sonnaert, Rassart, Gauquier, & Cavatorta, 2010; Becker et al., 2005; Flössel, Hahn,

Schmitter, & Erfurt, 2013; Weir, Suttner, Flynn, & McAuley, 2006; Wiedijk et al., 2016).

To analyze this specific cranium on a population level, we have performed PCA of the crania's frontal, lateral

and occipital views using image analysis based on convolutional neural networks. The skull in question was compared to 110 other female crania without this condition. The results revealed that the patient deviated from the rest of the female samples in frontal and posterior views, performing as an outlier. As this analysis is based on the black box approach, it could not identify traits or ratios that could lead to such results. However, specificities of the cranium could be explained by the visual inspection results and indices calculated from cranial measurements.

The skull shape was ultrabrachycephalic, which is not a frequent finding in populations ranging from 0.7% to 11% (Garson, 1887; Hossain, Lestrel, & Ohtsuki, 2004). The skull exhibited depression on the posterior part, and unsymmetrical flattening of the entire occiput indicated that this could be a case of plagiocephaly (Bessell-Browne & Thonell, 2004). Although plagiocephaly was not detected using CVAI that was below the threshold of 3.5, TDD indicated that this person had lateral deformational plagiocephaly in the mild form. This could be related to the divided parietal bone, the unsymmetrical position of the sagittal suture, and depression located at the posterior half of the sagittal suture.

Except for the divided parietal bone, this skull also exhibited several distinct cranial anatomical variations: asterion, lambda, and lambdoid ossicles, parietal foramen, frontal groove, supratrochlear notch, mastoid foramen, foramen ovale, zygo-facial foramina, and condylar canal. It is interesting to notice that most of these traits were bilateral, thus probably not attributed to the divided parietal bone. In contrast, an asterion and a lambdoid ossicle were positioned on the left half of the skull and were probably related to this finding.

This person exhibited no clinical manifestations that could be related to these cranial variations. Nevertheless, it allowed us to study the rare condition and related manifestations in cranial variations. This is important for assessing its potential identification value in forensic anthropology and when conducting bioanthropological population studies and studying possible familiar relationships in historical identifications or intracemetery relations (Zupanić Slavec,

2012). The usefulness of this trait in the archeological context for accessing family relationships or population affinity is still unknown. Although Hauser and De Stefano presume that there is a genetic background for the expression of this trait (Hauser & De Stefano, 1989), the heritability of this trait has not been confirmed. Since the present study reported the trait prevalence on limited sample size, further studies planned within the project Forensic Identification of Human Remains Using MSCT Image Analysis (CTforID) should reveal more details on this and other cranial variation both of modern and ancient population that inhabited the area of Croatia.

Funding

This study was funded by the Croatian Science Foundation, Installation Research Project no. HRZZ-UIP2020-02-7331 - Forensic identification of human remains using MSCT image analysis (CTforID).

References

- Abdel-Salam, G. M. H., Abdel-Hadi, S., Thomas, M. M., Eid, O. M., Ali, M. M., & Afifi, H. H. (2014). Gómez-López-hernández syndrome versus rhombencephalosynapsis spectrum: A rare co-occurrence with bipartite parietal bone. *American Journal of Medical Genetics Part A*, 164(2), 480–483.
- Angonese, A., Sonnaert, M., Rassart, A., Gauquier, N., & Cavatorta, E. (2010). Skull fracture or bipartite parietal bone. *Archives de Pediatrie: Organe Officiel de La Societe Francaise de Pediatrie*, 17(4), 391–393.
- Becker, D. B., Cheverud, J. M., Govier, D. P., & Kane, A. A. (2005). Os parietale divisum. *Clinical Anatomy: The Official Journal of the American Association of Clinical Anatomists and the British Association of Clinical Anatomists*, 18(6), 452–456.
- Berry, R. J. A. (1909). A case of os parietale bipartitum in an Australian aboriginal skull. *Journal of Anatomy and Physiology*, 44(Pt 1), 73.
- Bessell-Browne, R. J., & Thonell, S. (2004). Bipartite parietal bone: a rare cause of plagiocephaly. *Australasian Radiology*, 48(2), 248–250.
- Bhatt, A. A., Hunsaker, J., & Kalina, P. (2014). Pearls and pitfalls of pediatric head trauma imaging. *Applied Radiology*, 43, 10.
- Callejas Pastor, C. A., Jung, I.-Y., Seo, S., Kwon, S. Bin, Ku, Y., & Choi, J. (2020). Two-dimensional image-based screening tool for infants with positional cranial deformities: A machine learning approach. *Diagnostics*, 10(7), 495.

- Fenton, L. Z., Sirotiak, A. P., & Handler, M. H. (2000). Parietal pseudofracture and spontaneous intracranial hemorrhage suggesting nonaccidental trauma: report of 2 cases. *Pediatric Neurosurgery*, 33(6), 318–322.
- Flössel, U., Hahn, G., Schmitter, S., & Erfurt, C. (2013). Fallstrick: Os parietale bipartitum. *Rechtsmedizin*, 23(6), 482–484.
- Garson, J. G. (1887). The Cephalic Index. *The Journal of the Anthropological Institute of Great Britain and Ireland*, 16, 11–17.
- Goss, C. M. (1954). *Gray's Anatomy*. Philadelphia: Lea & Febiger.
- Gray, H. (1901). *Gray's Anatomy* (1995th ed.). New York: Barnes and Noble.
- Hauser, G., & De Stefano, G. F. (1989). *Epigenetic variants of the human skull*. Stuttgart: Schweizerbart'sche Verlagsbuchhandlung.
- Hossain, M. G., Lestrel, P. E., & Ohtsuki, F. (2004). Secular changes in head dimensions of Japanese females over eight decades. *Anthropological Science*, 407120011.
- Hrdlička, A. (1903). Divisions of the parietal bone in man and other mammals. *Bulletin of the American Museum of Natural History*, 9, 231–386.
- Langley, N. R., Jantz, L. M., Ousley, S. D., Jantz, R. L., & Milner, G. (2016). *Data collection procedures for forensic skeletal material 2.0*. Knoxville, Tennessee: The University of Tennessee.
- Looman, W. S., & Flannery, A. B. K. (2012). Evidence-based care of the child with deformational plagiocephaly, Part I: assessment and diagnosis. *Journal of Pediatric Health Care*, 26(4), 242–250.
- Prado, P. S. A., García-Donas, J. G., Langstaff, H., Cunha, E., Kyriakou, P., & Kranioti, E. F. (2016). Os parietale partitum: Exploring the prevalence of this trait in four contemporary populations. *Homo*, 67(4), 261–272.
- Sanchez, T., Stewart, D., Walvick, M., & Swischuk, L. (2010). Skull fracture vs. accessory sutures: how can we tell the difference? *Emergency Radiology*, 17(5), 413–418.
- Shapiro, R. (1972). Anomalous parietal sutures and the bipartite parietal bone. *The American Journal of Roentgenology Radium Therapy and Nuclear Medicine*, 115(3), 569–577.
- Simonyan, K., & Zisserman, A. (2015). Very deep convolutional networks for large-scale image recognition. *3rd International Conference on Learning Representations, ICLR 2015 - Conference Track Proceedings*, 1–14.
- Topinard, P. (1885). Éléments d'anthropologie générale. *Bulletins de La Société d'anthropologie de Paris*, 1(8), 14–17.
- Weir, P., Suttner, N. J., Flynn, P., & McAuley, D. (2006). Normal skull suture variant mimicking intentional injury. *British Medical Journal*, 332(7548), 1020–1021.
- Wiedijk, J. E. F., Soerdjbalie-Maikoe, V., Maat, G. J. R., Maes, A., Van Rijn, R. R., & De Boer, H. H. (2016). An accessory skull suture mimicking a skull fracture. *Forensic Science International*, 260, e11–e13.
- Zupanič Slavec, Z. (2012). *New method of identifying family related skulls: Forensic medicine, anthropology, epigenetics*. Springer Science & Business Media.