

Sex estimation by the patterns of lip impressions (cheiloscopy) : an analysis of a Croatian sample and a scoping review

Paušić, Mihaela; Ekštajn, Helena; Brkić, Stela; Jašinski, Martina; Utrobičić, Ana; Kružić, Ivana; Bašić, Željana

Source / Izvornik: **ST-OPEN, 2021, 2, 1 - 37**

Journal article, Published version

Rad u časopisu, Objavljena verzija rada (izdavačev PDF)

<https://doi.org/10.48188/so.2.8>

Permanent link / Trajna poveznica: <https://um.nsk.hr/um:nbn:hr:227:839662>

Rights / Prava: [Attribution 4.0 International](#)/[Imenovanje 4.0 međunarodna](#)

Download date / Datum preuzimanja: **2025-01-30**

SVEUČILIŠTE
U
SPLITU



SVEUČILIŠNI
ODJEL ZA
FORENZIČNE
ZNANOSTI

Repository / Repozitorij:

[Repository of University Department for Forensic Sciences](#)



UNIVERSITY OF SPLIT


dabar
DIGITALNI AKADEMSKI ARHIVI I REPOZITORIJI

Sex estimation by the patterns of lip impressions (cheiloscopy) – an analysis of a Croatian sample and a scoping review

Mihaela Paušić¹ ,
Helena Ekštajn¹ ,
Stela Brkić¹, Martina
Jašinski¹, Ana
Utrobičić², Ivana
Kružić¹ , Željana
Bašić¹ 

¹University of Split, University
Department of Forensic Sciences, Split,
Croatia

²University of Split, School of Medicine,
Split, Croatia

Correspondence to:

Mihaela Paušić
University of Split, University Department
of Forensic Sciences, Ruđera Boškovića 33,
21000 Split
mihaela.pausic9@gmail.com

Cite as:

Paušić et al. Sex estimation by the patterns
of lip impressions (cheiloscopy) – an analysis
of a Croatian sample and a scoping review.
ST-OPEN. 2021; 2: e2021.2013.10.

DOI:

<https://doi.org/10.48188/so.2.8>

Aim: To determine whether there is sexual dimorphism of lip prints' morphological features in the Croatian population and to provide a scoping review for the accuracy of sex estimation on lip prints.

Methods: The study on the Croatian population included 88 male and 88 female (median age 25, range 18 - 50) participants. Lip prints were analyzed by quadrant, and then the predominant pattern on the entire lip was observed. A systematic search of the relevant bibliographical databases was conducted, including Medline, Scopus, Web of Science Core Collection (WoSCC), and Cinahl (October 23rd, 2020). OpenGrey, Open Science Framework, and Science.gov databases were searched for grey literature. Findings were reported in the narrative form in accordance with the PRISMA Extension for Scoping Reviews (PRISMA-ScR) checklist. A total of 80 studies were included.

Results: The study of sexual dimorphism of lip prints in the Croatian population showed that there were no statistically significant differences between males and females; and when all quadrants were considered together ($\chi^2 = 3.625$, $P = 0.459$), sex could be estimated for only 55.7% of persons. Twenty-nine studies (36.3%) did not find differences between males and females, and 34 (42.5%) found sexual dimorphism only in some of the lip parts and some quadrants. The assessment of examined studies showed that only six studies met all quality criteria.

Conclusion: There is no forensically significant sexual dimorphism in lip prints in the Croatian population. The scoping review showed that sex estimation using lip prints should not be used as evidence in court as the present methodology is not reliable and the potential rate of error is unknown.

Introduction

Lip prints, similar to fingerprints, are unique, and can be crucial in the process of individualization [1]. As fingerprints are used to estimate other biological characteristics such as sex [2] and height [3], the usefulness of the lip prints has also been widely studied in sex estimation. Literature suggests that use of lip prints can aid in estimating the similarity between child and parents [4, 5] and can also be used to examine sexual dimorphism with a variety of results ranging from non-dysmorphic to highly dysmorphic [6, 7].

The main critiques of lip print analysis are the lack of widely accepted methodology for trace evidence collection, analysis, and interpretation; lack of data about population and regional diversity; as well as any ageing effects. In the 1999 United States court case *People v. Davis*, the appeal for a murder conviction concluded that the discipline of lip print analysis did not exist in the scientific community, that there was not any established training or certification, and that the methodology was vague [8]. To be more precise, there is no uniform methodology of studying the lines on the lips, i.e., it is not defined how the sample is taken, how is it analyzed, whether the predominant sample of a particular part of the lip print is taken, whether there is an error within and between observers, etc. So far, neither the repeatability of the method nor the reliability have been determined.

Similar to various other populations, Croatian sample has previously been studied. In that study, lip print differences between sexes were observed, but the sample was relatively small [9]. Keeping that gap in literature in mind, we approached sex estimation using lip print morphology in two ways with the hypothesis that there is no difference in the lip prints of males and females. First, we conducted a study on the Croatian sample to test the methodology and sexual dimorphism of lips. In the second step, we conducted a scoping review of all available studies on sexual dimorphism of lip prints.

Methods

Analysis of sexual dimorphism

We performed a cross-sectional study on a convenient sample of adults of both sexes from the Republic of Croatia from January to March 2019. The study included 176 participants aged 18 to 50 (median age 25), with an equal number of women and men. The research was approved by the ethics committee of the University Department of Forensic Sciences, the University of Split (approved on January 24, 2019, class: 003-08/18-06/00013; code: 2181-227-05-01-18-0007).

Participants

The participants were mostly recruited at the University of Split, but some samples were collected in other regions (Split-Dalmatia, Osijek-Baranja, Karlovac County, as well as the City of Zagreb). Only data about sex and age were collected. Participants who were allergic to some of the ingredients of lipsticks and/or adhesive tapes and those who had anomalies of the lips, viscerocranium or teeth were excluded from the research. The procedure

of collecting the samples, applying lipstick, and lip print exemption was explained to the participants prior to sample collection.




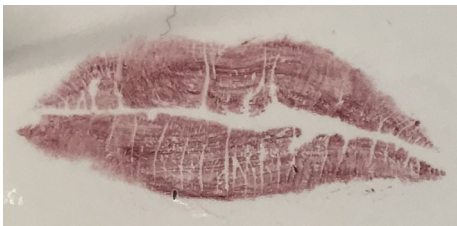
Materials

The materials used in this study were: two types of lipstick (Essence Colour Boost, Vinylicious, Essence, Italy and Catrice Ultimate Colour, 480 Red Side Black, Catrice, Luxembourg), cotton swabs, adhesive tape, white A4 paper, wet wipes, and scanner (Canon image RUNNER ADVANCE C3320, Canon Inc., Tokyo, Japan).

Pilot study - selection of the lip stick color and lip print exemption

First, the pilot study was conducted with six participants to select the methods for lip print collection and the color of lipstick that was most visible (MP, HE, SB, MJ, IK, ŽB). Four different methods with two types of lipsticks were used (**Table 1**) using the data from previous research [1, 4, 9, 10].

Table 1. Methods for collecting lip prints with two types of lipsticks

Lip print generation method	Lipstick type	
	Lipstick 1 Essence Colour Boost, Vinylicious, Essence, Italy	Lipstick 2 Catrice Ultimate Colour, 480 Red Side Black, Catrice, Luxembourg
Closed mouth, print left directly on white paper	 a	 b
Partially open mouth, print left directly on white paper	 c	 d
Closed/Partially open mouth, print left on adhesive tape that was then fixed on white paper	 e	 f
Closed/Partially open mouth, print left directly on white paper, which was then fixed with adhesive tape	 g	 h

Pilot research tested the visibility of lip prints and concluded that the best method of collecting lip prints was with darker lipstick (Catrice Ultimate Colour, 480 Red Side Black, Catrice, Luxembourg) and closed and/or partially open mouths on white paper fixed with adhesive tape.

Sample collection methodology

Dark lipstick was used to collect the lip prints; it was applied to dry lips with a cotton swab. Lip prints were left on white A4 paper which was divided into two parts: lip prints with a closed mouth (a) and lip prints with partially open mouth (b).

After the first lip print (a), the lipstick was once again applied with a new cotton swab for the second lip print (b). Cotton swabs were changed between each application of lipstick to avoid contamination. For each sample (closed/partially open mouth), it was necessary to leave at least two lip prints which were eventually fixed with adhesive tape. The remnants of lipstick were removed with wet wipes. All collected samples were scanned in black and white and in color (300 dpi) and analyzed in Microsoft Photos 2010 and Microsoft Excel 2010 (Microsoft Office 2010, USA). Scanned lip prints were divided into six types (IA-V) [11] (**Figure 1**) according to the Suzuki and Tsuchihashi classification [12]:

Type IA – a vertical line from the beginning to the end of the lip

Type IB – a vertical line to half lip

Type II – a vertical line with a branched end

Type III – intersected lines

Type IV – mesh pattern line

Type V – irregular, indeterminate lines.

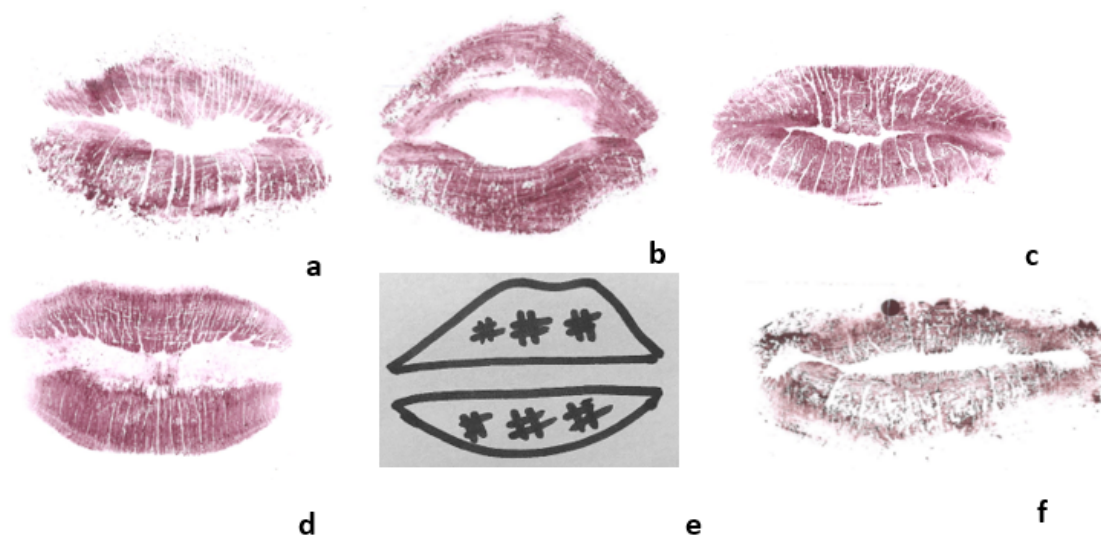


Figure 1. Lip prints classification according to Suzuki and Tsuchihashi [12]: (a) Type IA, (b) Type IB, (c) Type II, (d) Type III, (e) Type IV, (f) Type V.

For classification of the lip prints, the observers were blinded (every sample was coded). Each lip print was divided into four quadrants and analyzed starting from the upper right (UR), upper left (UL), lower left (LL) to lower right (LR) lips. The lip parts were enlarged in the Microsoft Photos 2010 program (Microsoft, Washington, 2010) to analyze the characteristic lines as efficiently as possible. Each quadrant was first analyzed separately and then the predominant pattern of the entire lip was scored (MP, HE).

Statistical analysis

All analyzed data were entered into a database in Microsoft Excel (Microsoft Office 2010, USA) and statistical analysis was performed in SPSS (ver. 18; SPSS Inc, Chicago, IL, USA) with a statistical significance level set at $P \leq 0.05$. Descriptive statistics encompassed numbers and percentages for categorical variables. The association between lip parts was measured using a correlation test. Discriminant analysis was used to define the existence of sexual dimorphism, with calculation of the percent of correctly classified cases as the validation measure.

Scoping review of the literature

The study was registered on Open Science Network <https://osf.io/9ytbh/>. Findings were reported in a narrative form in accordance with the PRISMA Extension for Scoping Reviews (PRISMA-ScR) checklist [13]. The two authors (MP and HE) independently extracted the data, and in case of disagreement, they consulted the third author (ŽB) to reach an agreement. Cohen's Kappa (K) was calculated to evaluate the interobserver agreement.

Eligibility criteria

Studies were included if they explicitly investigated sexual dimorphism using lip prints, irrespective of the study design. Editorials, letters, and methodology studies were excluded. This scoping review focused on exploring the accuracy of assessing sexual dimorphism using lip prints.

Search strategy

The first step included an initial selective search of relevant databases and was followed by the analysis of the text words contained in the titles, the abstracts, and the index terms used to describe the articles [14]. Then, a comprehensive literature search was conducted including both published and unpublished literature. The search strategy was developed in cooperation with an experienced librarian (AU) from the University of Split, School of Medicine. A systematic search of the relevant bibliographical databases - including Medline, Scopus, Web of Science Core Collection (WoSCC), and Cinahl - was conducted. The search developed for Medline was appropriately adapted for searching in other databases. We also searched the OpenGrey database for grey literature. The search was performed on October 23, 2020. References of other studies were screened for potentially eligible studies, and studies citing included studies were searched through for relevant citation databases. There were no limitations in terms of language or date, except for searching the

grey literature. These were limited to studies written in English due to an expected large number of possible study results. The full search strategy used for Medline is available in [Appendix 1](#).

Study selection

Screening of the search results was carried out using the EndNote tool (EndNote X9, Clarivate, Philadelphia, PA, 2013). Titles and abstracts of all studies and any full texts were checked for eligibility by two independent reviewers (MP, HE). Both authors needed to reach an agreement for a study to be included in the review. In case of a disagreement, the third reviewer (ŽB) was consulted.

Quality assessment

The quality of included studies was assessed using JBI Critical Appraisal Tools [15]. Two researchers (MP, HE) appraised the studies. As the JBI Critical Appraisal Tools [15] are intended for medical research, some of the validation criteria were adjusted to better fit the forensic sciences ([Appendix 2](#)).

Data extraction

Two authors (MP, HE) independently extracted data from the included studies. A data extraction form was developed and piloted by ŽB before the final data extraction. The extraction table was piloted by MP and HE by analyzing data from five randomly chosen papers from the list. The pilot table was not changed afterward. The data extraction form included the following information: study design (according to the classifications in original studies/papers), setting (country, institution), participants (number of participants, sex, if the sample size calculator was used, and inclusion and exclusion criteria), interventions (classification methodology, number of quadrants observed, collection, and analysis methodology), outcomes (if the inter and intraobserver variability was tested, sexual dimorphism, and classification rate), and funding.

Summarizing and analyzing data

The two authors (MP and HE) independently extracted the data, and in case of disagreement consulted the third author (ŽB) to reach an agreement. Quantitative pooling of the individual studies' data was not possible due to the high diversity of the included studies; therefore, results were presented descriptively.

Results

Sexual dimorphism of the Croatian population

Separate examination of each quadrant showed that Type III was the most frequent pattern (54%), followed by Type II (32%), Type IA (10%), Type V (3%), and Type IB (1%). Type IV was not present in the analyzed samples. The upper lips showed dominance of Type III

(57%), followed by Type II (28%), Type 1A (11%), Type V (3%), and Type 1B (1%). As with the upper lips, the lower lips showed the highest percentage of Type III (50%), followed by Type II (36%), Type 1A (10%), and Type V (4%) while Types 1B and IV were not present on the lower lips. Correlation testing showed a linear correlation between the lip patterns on the upper and lower lips (including the left and right sides) for the whole sample (male and female together) with a correlation value of 0.581 to 0.886 ($P < 0.001$).

The analysis of sexual dimorphism showed that there were no statistically significant differences between males and females when all quadrants were considered together ($\chi^2 = 3.625$, $P = 0.459$). Sex could be estimated for only 55.7% of persons. In the second method where the predominant pattern was observed on the entire lips, the study showed that the Type II pattern was the most common (for both men and women) with 30%, then Type IA with 28% followed by Type III with 25%, and the least represented types were Type V with 14%, Type IB with 3%, and Type IV with 0%. Statistically significant differences between males and females were not found in the predominant morphology of the lips (Fisher's exact test, $P = 0.242$).

Scoping review

The results of the scoping review process are shown in [Figure 2](#).

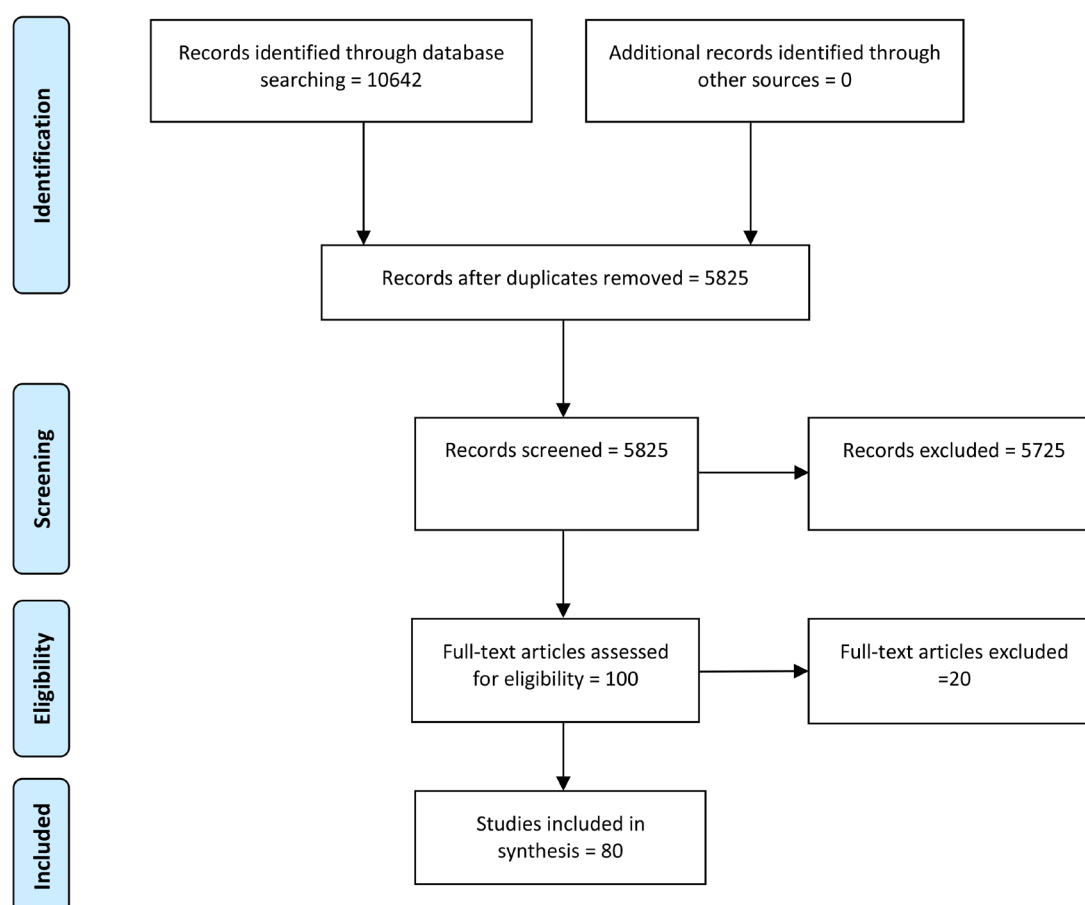


Figure 2. PRISMA flow diagram for the scoping review process.

The number of records identified through database searching was 10,642 while the final number of included studies was 80. A list of studies included in the scoping review, along with details regarding their lip print research, is shown in [Table 2](#). Although we initially found 100 papers, 16 were not available as full texts (the authors did not respond to several e-mail requests for full texts) and four studies were excluded as they did not analyze sexual dimorphism, thus leaving 80 studies for analysis ([Table 2](#)).

In the experimental part of the study (on the sample from the Croatian population), it was not possible to pinpoint differences between males and females by analyzing quadrants or the overall predominant appearance of lip prints. Considering the collection methods, our research has shown that the method by which the clearest lip prints are obtained is with a darker lipstick and with a closed and/or partially open mouth. In this study, we did not opt for only one method (closed or partially open mouth) because depending on the shape and/or thickness of the lips, as well as the strength of pressure applied to the paper, both methods were sometimes more appropriate for observing morphological features.

To evaluate the analyzed papers in the scoping review, we used the critical appraisal of research ([Appendix 2](#)) and the PRISMA-ScR checklists [15].

To answer the question, *Were the criteria for inclusion in the sample clearly defined?* we considered a study “unclear” and marked it with one asterisk if there were no defined characteristics of what the authors considered a healthy person (e.g., lips without trauma, damage, etc.) and where only the population and age of participants were defined. A total of 14 studies were considered “unclear” in this category. The studies marked “unclear” with two asterisks were those where the authors stated that they had excluded any participants with undesirable pathologies, but they did not define them. There were six such studies. The studies marked “unclear” with three asterisks were those that stated that their exclusion criteria were hypersensitivity to cosmetics and lesions on the lips. Two studies were found with these criteria. Six other studies were considered combinations of the above unclear categories, so we could not opt for one classification. Overall, the studies that named all the inclusion and exclusion criteria were marked as “yes”; 45 studies fell into this criterion. Seven of the studies did not meet any inclusion or exclusion criteria. Thus, only approximately half of the studies completely fulfilled these criteria. The question *Were confounding factors identified?* considered the same criteria as previously described, thus the number of “yes”, “no”, and “unclear” is the same as in the previous question.

Table 2. The results of the scoping review on the sexual dimorphism of lip prints

Study id	Study design	Setting		Participants			Interventions			Outcomes		
		Country	Place/ participants	Number	Sex	Used sample size calculator	Inclusion/ Exclusion criteria	Classification methodology/number of parts the lips were divided to	Collection/analysis methodology	Inter/intraobserver variability tested?	Results differences between sexes/% of correctly classified	Funding
Ahmed, S. A., et al., 2018 [16]	Cross-sectional study	Egypt	Other, volunteers	221	105 M, 116 F	No	Exclusion criteria: subjects with inflammations, scars, deformities, or history of plastic surgery of the lips	Suzuki and Tsuchihashi [12]/4	Dark lipstick, print taken to paper. Visualized with a magnifying lens	*NA	No/NA	NA
Ahuja, P., et al., 2018 [17]	Cross-sectional study	India	Other	100	50 M, 50 F	No	Inclusion criteria: healthy individuals, 18-25 years old, Gujarati population	Suzuki and Tsuchihashi [12]	Dark brown lipstick taken with cellophane tape on white bond paper. Visualized with a magnifying lens and with a stereomicroscope	NA	No/NA	†None
Alzapur, A., et al., 2017 [18]	Cross-sectional study	India	University	100	50 M, 50 F	No	Inclusion criteria: young adults without any disease related to lips, with normal lip mucosa. Exclusion criteria: subjects having any gross congenital deformities of lips (e.g., cleft lip), and those with any inflammation, lipstick allergy, and with any kind of disease	Suzuki and Tsuchihashi [12]/4	Dark lipstick, rubbed, print taken to folded bond paper. Visualized with a magnifying lens	NA	No/NA	NA
Amith, H. V., et al., 2012 [19]	Cross-sectional study	Tibet, India	Other	1500	No	No	Inclusion criteria: subjects 10-25 years old and signed informed consent	Suzuki [20]/4	Dark shaded lipstick applied on the lips using a cotton swab. Lip impression made on a strip of cellophane tape and stuck onto a white paper, recorded on the consent form. Visualized with a magnifying lens	NA	‡Yes, for males Type III and for females Type IV/NA	NA
Anu, V., et al., 2020 [21]	Cross-sectional study	India	University	500	250 M, 250 F	No	Inclusion criteria: subjects with morphologically healthy look, devoid of congenital or developmental abnormalities	Suzuki and Tsuchihashi [12]/6	Dark colored lipstick applied by a lipstick applicator brush. Print taken with cellophane tape and then stuck to chart sheet. Visualized with a magnifying glass	NA	Yes/NA	None
Augustine, J., et al., 2008 [22]	Cross-sectional study	India	Families	600	280 M, 320 F	No	Inclusion criteria: Patients without deformity, scars, abnormalities	Suzuki and Tsuchihashi [12]/4	Dark lipstick, dried on lips, print taken to scotch tape and cellophane tape, then stuck to a paper. Scanned and analyzed in Adobe Photoshop	NA	Only in lateral segments/NA	NA

Table 2. Continued

Study id	Study design	Setting		Participants			Interventions		Outcomes			
		Country	Place/participants	Number	Sex	Used sample size calculator	Inclusion/Exclusion criteria	Classification methodology/the lips were divided to	Collection/analysis methodology	Inter/intraobserver variability tested?	Results differences between sexes/% of correctly classified	Funding
Aziz, M. H., A., et al., 2016 [23]	Cross-sectional study	Egyptians, Malaysians	University	120 (60 Egyptians, 60 Malaysians)	60 M, 60 F	No	Exclusion criteria: subjects with any known hypersensitivity to lipstick or evidence of any pathology such as inflammation, mucocoele, cicatrization, and deformities such as cut marks or lesions of lips	Suzuki and Tsuchihashi [12]/4	Lipstick, print taken to paper, then stuck to a (filter) paper. Visualized with a magnifying lens	NA	Yes, in some quadrants/68.3% Egyptian population, 65% Malaysian population	NA
Babladi, P.I., et al., 2012 [24]	Cross-sectional study	India	University	124	66 M, 58 F	No	Inclusion criteria: subjects aged 18-22, without any lesion, whether active or passive on the lips. Exclusion criteria: known hypersensitivity to lipsticks	Suzuki and Tsuchihashi [12]/1 (middle segment of lower lip)	Lipstick applied on the lips, lip-prints obtained on a simple bond paper and coded based on the name and the sex of the individuals	NA	Yes, type III in males and type I in females/53.03% in males, 46.55% in females	NA
Badiye, A., et al., 2016 [25]	Cross-sectional study	India	Other (specific subpopulation)	400	200 M, 200 F	No	Inclusion criteria: healthy subjects free from any oral pathology, inflammation, or deformities such as cleft lip, cut marks or lesions of the lip	Suzuki and Tsuchihashi [12]/2 (central 1 cm ² of both the upper and lower lips)	Photographed in Frankfurt plane, analyzed on computer. Only the central lip part	Yes/Kappa values "very good"	Yes, for type II in males and type IV in females; significant association at a level >95% and >99% between sex and lip print types/NA	NA
Bai, J. S., et al., 2018 [26]	Correlative study	India	University	300	150 M, 150 F	No	The lips of each subject were thoroughly examined clinically for any deformity, scars, or abnormality. Exclusion criteria: any abnormality	Tsuchihashi [27]/1 (middle part of the lower lip)	Lipstick, dried on lips, print taken to cellophane tape, then stuck to a paper. Visualized with a magnifying lens	NA	Yes ($P < 0.0001$)/80%	NA
Ballur, M.S., et al., 2016 [28]	Cross-sectional study	India	University	200	100 M, 100 F	No	Exclusion criteria: subjects with gross deformities of lips like cleft lip, ulcers, traumatic injury on the lips and cases with known allergy to the lipstick	Tsuchihashi [27]/1 (entire lower lip); Vahanwala [29]/1 (entire lower lip)	Bright red color and nonglossy lipstick was applied on the lips, then cellophane tape was applied on the lips and the prints were taken on unglazed white bond paper. Visualized with a magnifying lens	NA	Yes, for types I, I' and II in females and types III, IV and V in males/92% females and 83% males	None

Table 2. Continued

Study id	Study design	Setting			Participants		Interventions			Outcomes		
		Country	Place/participants	Number	Sex	Used sample size calculator	Inclusion/Exclusion criteria	Classification methodology/number of parts the lips were divided to	Collection/analysis methodology	Inter/intraobserver variability tested?	Results differences between sexes/% of correctly classified	Funding
Bansal, A.K., et al., 2019 [30]	Cross-sectional study	India	University	200	100 M, 100 F	No	Inclusion criteria: subjects between 18-21 years. Exclusion criteria: subjects with congenital lesions, defects, diseases and injuries over the lips and persons with known hypersensitivity to lipstick	Suzuki and Tsuchihashi [12]/6	Lipstick was applied on the lips. First lip print taken directly on folded white bond paper and second lip impression taken on a simple glass slide	NA	Yes, type IV in males, and type I in females/NA	NA
Bansal, N., et al., 2014 [31]	Cross-sectional study	India	University Hospital	5000	2500 M, 2500 F	No	NA	Tsuchihashi [27]/1 (middle part of the lower lip)	Dark lipstick, dried on lips, print taken to cellophane tape, then stuck to a paper. Visualized with a magnifying lens	NA	Yes, for types I, I', II in females and types III, IV in males/56.6 % of males and 43.4% of females correctly classified	None
Basheer, S., et al., 2017 [32]	Correlative study	India	University	858	471 M, 387 F	No	Inclusion criteria: signed informed consent; participants native to North Kerala. Exclusion criteria: patients with any congenital lip deformity, acute infection, or any other disease of the lips; patients with known hypersensitivity to lipstick	Suzuki and Tsuchihashi [12]/4	Lipstick, print taken to cellophane tape, then stuck to a paper. Visualized with a magnifying lens	NA	Only in upper lip/NA	NA
Bharat Kumar, E.D., 2017 [33]	Cross-sectional prospective study	India	School	200	100 M, 100 F	No	Inclusion criteria: subjects between 10-16 years irrespective of their caste, religion, dietary habits, and socio-economic status. Exclusion criteria: gross deformities of lips like cleft lip, ulcers, and traumatic injuries on lips; known allergy to the lipstick used in the study	Suzuki and Tsuchihashi [12]/4	Dark lipstick applied on the lips, lips print taken with cellophane tape and then stuck on white paper. Visualized with a magnifying lens	NA	Yes, in male types I and III/NA	None
Bharathi, S., et al., 2015 [34]	Cross-sectional study	India	University and hospital	100	24 M, 76 F	No	Inclusion criteria: subjects with no lesions (active or passive). Exclusion criteria: subjects with hypersensitivity to lipstick	Tsuchihashi [27]/4	Lipstick applied on the lips, taken with cellophane tape, and stuck to a paper. Visualized with a magnifying lens	NA	Yes, type Ia in males and type II in females/54% of males, 51% females	NA

Table 2. Continued

Study id	Study design	Setting			Participants			Interventions		Outcomes		
		Country	Place/participants	Number	Sex	Used sample size calculator	Inclusion/Exclusion criteria	Classification methodology/number of parts the lips were divided to	Collection/analysis methodology	Inter/intraobserver variability tested?	Results differences between sexes/% of correctly classified	Funding
Borase, A. P., et al., 2016 [35]	Cross-sectional epidemiological study	India	Other	496	326 M, 170 F	Yes (but not population size calculator, only healthy lips patients)	Inclusion criteria: subjects with no lesions on the lips	El Domiaty et al. [1]/6	Lip liner + dark lipstick, dried on lips, print taken to cellophane tape, then stuck to a paper. Scanned and visualized with a magnifying lens	NA	Yes - for some types on upper lip/NA	None
Chaudhari, S.H., et al., 2017 [36]	Cross-sectional study	India	People visiting medical college or living nearby	150	75 M, 75 F	No	Inclusion criteria: subjects 25-50 years old; with lips free from any pathology, having normal transition zone between the mucosa and skin. Exclusion criteria: individuals with known allergy to lipstick, inflammation of lips, trauma, malformation, deformity, surgical scars, facial palsy, and active lesions	Suzuki and Tsuchihashi [12]/4	Dark lipstick, applied on lips, print taken to cellophane tape, then stuck to a paper. Visualized with a magnifying lens	NA	Yes, type I, I' and type II in females and type III and type IV in males/NA	None
Costa, V.A., et al., 2012 [4]	Cross-sectional study	Portugal	Hospital patients	50	25 M, 25 F	No	Inclusion criteria: absence of lip lesions or abnormalities on lips and Portuguese geographical origin. Exclusion criteria: individuals with known hypersensitivity to lipsticks, inflammation, trauma, congenital, or other abnormalities of the lips	Suzuki and Tsuchihashi [12]/4	Dark lipstick rubbed before taking prints, white paper and cellophane tape. Photographed. Visualized with a magnifying lens	NA	Yes, for type III in males and type II females/64% males, 72% females	NA
Dey, A., et al., 2019 [37]	Cross-sectional study	India (sub-population)	University	280	138 M, 142 F	No	Exclusion criteria: subjects below 15 years, subjects with chapped lips or allergic reaction to lipstick and males with moustache covering the whole upper lip	Suzuki and Tsuchihashi [12]/4	Lipstick was applied with a brush, lip print taken with a cellophane tape and stuck on the white sheet	NA	Yes, in some quadrants/NA	NA
Divyadharsini, V., et al., 2019 [38]	Cross-sectional study	India	University	100	50 M, 50 F	No	Inclusion criteria: subjects between 20-30 from Saveetha Dental College and Hospital; healthy individuals free of congenital abnormalities, inflammation, trauma, or orthodontic treatment. Exclusion criteria: subjects allergic to lipstick or people not willing to participate	Suzuki and Tsuchihashi [12]/1 (the entire lip)	Lipstick applied with a brush, lip print taken with a cellophane tape and stuck on a white paper. Visualized using a magnifying glass	NA	Yes, type I in females and types IV (32%) and V (30%) in males/NA	NA

Table 2. Continued

Study id	Study design	Setting		Participants			Interventions		Outcomes			
		Country	Place/participants	Number	Sex	Used sample size calculator	Inclusion/Exclusion criteria	Classification methodology/number of parts the lips were divided to	Collection/analysis methodology	Inter-observer variability tested?	Results differences between sexes/% of correctly classified	Funding
Dixit, A., et al., 2019 [39]	Cross-sectional study	India (students from India and Africa)	University	20	10 M, 10 F	No	No	Suzuki and Tsuchihashi [12]/4	First applied lip balm, and then lipstick. Lip prints pressed to a white paper and preserved using a transparent cellophane tape. Examination by hand magnifier and stereomicroscope	NA	In some types and some quadrants/NA	None
El Domiaty, M.A., et al., 2010 [1]	Cross-sectional study	Saudi Arabia (region)	Other including 13 identical twins and 19 families	966	426 M, 540 F	No	Exclusion criteria: any inflammation, cicatrization, or deformity of lips	Renaud [40]/6	Dark lipstick, dried on lips, print taken to scotch tape and cellophane tape, then stuck to a paper, with three different methods	NA	No/NA	NA
Gouda, S., et al., 2017 [41]	Cross-sectional study	India	University	100	50 M, 50 F	No	Inclusion criteria: students with normal transition zone between the mucosa and skin and free from any pathology	Suzuki and Tsuchihashi [12]/4	Red color lipstick (non-glossy and non-metallic). Lip prints taken by rolling the paper on to the lips with application of slight, gentle pressure. The lips kept slightly separated and relaxed during manipulation. After taking the impression a cellophane strip was stuck on the paper. Visualized using a magnifying hand lens with direct light focused on it	NA	No/NA	None
Gupta, S., et al., 2014 [42]	Cross-sectional study	Probably India	Other	378	189 M, 189 F	No	Inclusion criteria: 18 - 30 years; subjects having full dentition; lips free from any pathology, having absolutely normal transition zone between the mucosa and skin; healthy subjects, free of congenital abnormalities, inflammation, trauma, and orthodontic treatment. Exclusion criteria: subjects with malformation, deformity, inflammation, trauma, surgical scars (e.g., operation for cleft palate), and other abnormalities of the lips and palate	Suzuki and Tsuchihashi [12]/4	Red and brown lipstick, print taken to cellophane tape, then stuck to a paper. Visualized using a magnifying lens	Yes, three observers/Calculated Kappa values/Varied between quadrants from poor to almost perfect	Intersecting pattern was the most common in females and branching pattern in males. Sexual dimorphism otherwise not compared/27.7% in females, 28.1% in males	Yes

Table 2. Continued

Study id	Study design	Setting			Participants		Interventions			Outcomes		
		Country	Place/participants	Number	Sex	Used sample size calculator	Inclusion/Exclusion criteria	Classification methodology/number of parts the lips were divided to	Collection/analysis methodology	Inter/intraobserver variability tested?	Results differences between sexes/% of correctly classified	Funding
Gupta, S., et al., 2011 [43]	Cross-sectional study	Probably India	Other	150	75 M, 75 F	No	Inclusion criteria: subjects having full dentition, lips free from any pathology, having normal transition zone between the mucosa and the skin. Exclusion criteria: subjects with malformation, deformity, inflammation, trauma, surgical scars (e.g., operation for cleft palate) and other abnormalities of the lips	Suzuki and Tsuchihashi [12]/4	Red (for females) and brown (for males) colored lipstick applied on lips, print taken to cellophane tape, then stuck to a paper. Visualized with a magnifying lens	NA	No/NA	NA
Hammad, M., et al., 2014 [6]	Cross-sectional study	Pakistan	University students	100	30 M, 70 F	No	Inclusion criteria: subject free from any active or passive lesions on lips. Exclusion criteria: subjects with gross deformities of lips like cleft lip, ulcers, traumatic injuries on lips, known allergy to the lipstick used in the study	Suzuki and Tsuchihashi [12]/1 (the entire lip)	Lipstick, print taken to paper	NA	No/NA	NA
Herrera, L.M., et al., 2018 [44]	Cross-sectional study	Brazil	Other (volunteers)	50	25 M, 25 F	No	Inclusion criteria: subjects without any kind of inflammation or lesions /malformations on the lips and any other characteristics that could allow their recognition. Exclusion criteria: subjects with allergy to lip cosmetics	Suzuki and Tsuchihashi [12]/6	Red non-metallic lipstick applied on lip. Print taken to cellophane tape, then stuck to a paper. Lip prints provided on different supports: white sheet of paper, drinking glass and CDs. Lip prints photographed with a digital camera	NA	No /NA	NA
Ishaq, N., et al., 2018 [45]	Cross-sectional study	Pakistan	University	250	125 M, 125 F	Yes	Inclusion criteria: students. Exclusion criteria: subjects sensitive to lipstick and having lesions, trauma, malformation, and deformity, or scars	Tsuchihashi [27]/1 (the entire lip)	Dark lipstick, print taken to cellophane tape, then stuck to a paper	NA	Yes, for males Type III and for females Type I/76.8%	NA

Table 2. Continued

Study id	Study design	Setting			Participants		Interventions			Outcomes		
		Country	Place/participants	Number	Sex	Used sample size calculator	Inclusion/Exclusion criteria	Classification methodology/number of parts the lips were divided to	Collection/analysis methodology	Inter/intraobserver variability tested?	Results differences between sexes/% of correctly classified	Funding
Jeergal, P. A., et al., 2016 [46]	Cross-sectional study	India	Other	200	100 M, 100 F	No	Exclusion criteria: participants with any evidence of disease and injury of the lips, dry lips, cleft lip, laceration, and scars	Suzuki and Tsuchihashi [12]/8	Lipstick, dried on cellophane tape, then stuck to a paper. Scanned and analyzed on computer	NA	Yes/NA	None
Kapoor, N., et al., 2017 [47]	Cross-sectional study	India	Other (subpopulation)	200	100 M, 100 F	No	Inclusion criteria: only healthy subjects, free from any oral pathologies, inflammation, abnormalities, or deformities such as cleft lip, cut marks, surgical scars, or lesions of the lip	Suzuki and Tsuchihashi [12]/4	Photographed in Frankfurt plane, analyzed on computer	Yes, two different examiners/ Kappa value "good" to "very good"	Yes, type I for males and type III for females/NA	NA
Karki, R.K., 2012 [48]	Cross-sectional study	Nepal	University students	150	75 M, 75 F	No	Inclusion criteria: lips free from any pathology, having normal transition zone between the mucosa and skin	Suzuki and Tsuchihashi [12]/4	Brown or red colored lipstick applied on cleaned lips; taken to white papers; fixed on cardboard	NA	Yes, Type I and I' was more common in males, Type I was rare in females/NA	NA
Kaul, R., et al., 2015 [49]	Randomized cross-sectional study	India	General	755	375 M, 380 F	No	Inclusion criteria: individuals aged above 1 year with lips free from any pathology and having absolutely normal transition zone between the mucosa and skin. Exclusion criteria: individuals with known allergy to lipstick, inflammation of lips, trauma, malformation, deformity, surgical scars, facial palsy, and active lesions of the lips	Tsuchihashi [27]/4	Lipstick, dried on lips; print taken to cellophane tape, then stuck to a paper. Visualized with a magnifying lens	NA	No/35.4% females; 17.4% males	NA
Kautilya, D.V., et al., 2013 [50]	Cross-sectional study	South India	University students	100	50 M, 50 F	No	Exclusion criteria: subjects with any lip anomalies or any active lesions on the lips and with any known allergy to lipstick	Suzuki and Tsuchihashi [12]/6	Dark lipstick, dried on lips; print (separately upper and lower lip) taken to cellophane tape, then stuck to a paper. Visualized with a magnifying lens	NA	Yes, in some lip parts/NA	None

Table 2. Continued

Study id	Study design	Setting			Participants		Interventions			Outcomes		
		Country	Place/participants	Number	Sex	Used sample size calculator	Inclusion/Exclusion criteria	Classification methodology/number of parts the lips were divided to	Collection/analysis methodology	Inter/intraobserver variability tested?	Results differences between sexes/% correctly classified	Funding
Kelasi, P.S.A., et al., 2019 [51]	Cross-sectional study	India	University students	50	25 M, 25 F	No	Exclusion criteria: subjects undergoing orthodontic treatment, presence of congenital lip abnormalities, inflammation or trauma of lips, hypersensitivity to lipsticks	Suzuki and Tsuchihashi [12]/6 (only some parts were analyzed)	A thin film of lipstick applied into cleaned and dried lips; the impressions of the lips taken on folded white bond papers	NA	Yes, type IV for males and type II for females/No	Yes
Kinra, M., et al., 2014 [52]	Cross-sectional study	India	Hospital	40	20M, 20F	No	Inclusion criteria: normal lips without any congenital malformations, traumatic injuries, or infectious disease. Exclusion criteria: patients with congenital lip lesions, medical history of disease in lips or traumatic injuries, and known hypersensitivity to lipstick	Tsuchihashi [27]/1 (middle part of the lower lip)	Dark lipstick, dried on lips using a brush on both the lips till the vermilion border. Print taken to a strip of cellophane tape on the glued/sticky portion, then stuck to a paper. Visualized with a magnifying lens	Yes/Good (Cohen kappa > 0,8)	No/NA	None
Koneru, A., et al., 2013 [53]	Cross-sectional study	India	University (two subpopulations)	60	30 M, 30 F	No	Inclusion criteria: subjects whose lips were free from any pathology such as inflammation, mucocoele, cicatrization, and deformities such as cut marks or lesions. Exclusion criteria: any known hypersensitivity to the lipstick that was used	Tsuchihashi [27]/4	Dark, bright, nonglossy lipstick, dried on lips, print taken to cellophane tape, then stuck to a paper. Visualized with a magnifying lens	NA	Yes, types IV and V for males and types I and I' for females/29,2%, 21,7% males and 43,3%, 30% females	NA
Krishnan, R. P., et al., 2016 [54]	Cross-sectional study	India	University	50	25 M, 25 F	No	Inclusion criteria: individuals with no lip or finger pathology, healthy periodontium, and dental cavity-free canines	Tsuchihashi [27]/1 (the entire lip)	Lip pencil + dark lipstick, print taken to cellophane tape, then stuck to paper. Visualized with a magnifying lens	NA	Yes, for types I and I' in females and type IV in males/NA	NA
Manikya, S., et al., 2018 [55]	Cross-sectional study	India	University (three subpopulations)	180	90 M, 90 F	Yes	Inclusion criteria: lips and rugae without any inflammatory disease, trauma, malformation, deformity, and scars	Tsuchihashi [27]/6	Vaseline + lipstick, rubbed, print taken to tape, then stuck to a paper. Visualized with a magnifying lens	NA	Yes, in some types, varies between subpopulations/61% males, 59% females	None

Table 2. Continued

Study id	Study design	Setting			Participants		Interventions			Outcomes		
		Country	Place/participants	Number	Sex	Used sample size calculator	Inclusion/Exclusion criteria	Classification methodology/number of parts the lips were divided to	Collection/analysis methodology	Inter/intraobserver variability tested?	Results differences between sexes/% of correctly classified	Funding
Mantilla Hernandez, J.C., et al., 2015 [56]	Cross-sectional study	Colombia	University	60	30 M, 30 F	No	Inclusion criteria: subjects without lesions on the lips. Exclusion criteria: subjects with known hypersensitivity to lipstick	Suzuki and Tsuchihashi [12]/1 (the middle third of the lower lip)	Red lipstick, white bond paper, adhesive tape. Visualized with a magnifying lens	NA	Yes, type V for females and type I for males/36,6% in females, 40% in males	NA
Moshfeghi, M., et al., 2016 [57]	Cross-sectional study	Iran	University, Hospital	96	22 M, 74 F	No	Inclusion criteria: absence of any inflammation, ulcer, pathology, deformity, or surgical scars on the lips, no history of physical trauma to the lips, no smoking and no lip chewing habits. Exclusion criteria: individuals allergic to cosmetics and subjects with non-Iranian ethnicity	Suzuki and Tsuchihashi [12]/6	Lips cleaned thoroughly by gently wiping a dipped roll of cotton wool in a povidone-iodine cleansing solution. Non-glossy oil-free lipstick gently applied to the vermillion on both upper and lower lips. Lip print made using scotch tape (pressure from the middle of the lips towards the corners); the tape glued to white paper. Visualized with a magnifying lens	Yes/Very good (weighted kappa >0.9)	Yes, in some lip parts/NA	NA
Multani, S., et al., 2014 [58]	Cross-sectional study	India	Other	200	100 M, 100 F	No	Exclusion criteria: subjects with any inflammation, trauma, congenital deformity, or any other disease of lips or known hypersensitivity	Suzuki and Tsuchihashi [12]/1 (the middle part of lower lip)	Dark eyeshadow, print taken to cellophane tape, then stuck to a paper. Visualized with a magnifying lens	NA	Yes, type III in males, type I in females/ varies in different age groups from 29.4% to 96.5%	NA
Nagalaxmi, V., et al., 2014 [59]	Cross-sectional study	India	Hospital	60	30 M, 30 F	No	Exclusion criteria: subjects with congenital anomalies, soft tissue surgeries, trauma, orthodontic treatment, malocclusions, attrition and other regressive alterations of teeth, caries free teeth, normal molar and canine relationship	Suzuki and Tsuchihashi [12]/6	Bright lipstick, dried on lips, print taken to cellophane tape, then stuck to a paper. Visualized with a magnifying lens	Yes/Kappa coefficient (73.33%)	Yes, for males type III and females type I/88,4% males, 81,7% females	NA

Table 2. Continued

Study id	Study design	Setting			Participants		Interventions			Outcomes		
		Country	Place/participants	Number	Sex	Used sample size calculator	Inclusion/Exclusion criteria	Classification methodology/number of parts the lips were divided to	Collection/analysis methodology	Inter/intraobserver variability tested?	Results differences between sexes/% of correctly classified	Funding
Nagasupriya, A., et al., 2011 [60]	Comparative (correlative) study	India	University	200	100 M, 100 F	No	Inclusion criteria: individuals free from any pathology of the lips or fingers Exclusion criteria:	Santos [61], Suzuki and Tsuchihashi [12]/4 (middle part of upper lip)	Dark lipstick, dried on lips, print taken to cellophane tape, then stuck to a paper. Visualized with a magnifying lens	NA	No/NA	NA
Nagpal, B., et al., 2015 [62]	Cross-sectional study	India, Malaysia	University students	60	20 M (12 Indians and 8 Malaysians), 40 F (18 Indians and 22 Malaysians)	No	Exclusion criteria: individuals with known hypersensitivity to lipsticks, with any malformation, inflammation, trauma, scar, or any other abnormality of the lip	Suzuki and Tsuchihashi [12]/6	Lipstick without oil or matte lipstick applied to cleansed lips using lipstick brushes. The prints made on sticky paper by placing between the lips. Visualized using a magnifying glass with light	NA	No/NA	NA
Naik, R., et al., 2017 [63]	Correlative study	India	University students	100	50 M, 50 F	No	Inclusion criteria: lips free from any pathology	Tsuchihashi [27]/6	The outline of the lips marked with a lip liner and then a red lipstick evenly applied with a lipstick brush. A lip print left on Whatman filter paper. Visualized using a magnifying lens	NA	No/NA	None
Negi, A., et al., 2016 [64]	Cross-sectional (correlative) study	India	General	200	100 M, 100 F	No	Exclusion criteria: subjects with any pathology of the lips and fingers that could affect the lip print and the fingerprint	Nagasupriy et al. [60]/1 (the middle-third portion of the lower lip) modified	Dark lipstick, print taken to cellophane tape, then stuck to a paper	NA	No/NA	None

Table 2. Continued

Study id	Study design	Setting			Participants			Interventions			Outcomes	
		Country	Place/participants	Number	Sex	Used sample size calculator	Inclusion/Exclusion criteria	Classification methodology/number of parts the lips were divided to	Collection/analysis methodology	Inter/intraobserver variability tested?	Results differences between sexes/% of correctly classified	Funding
Oliveira, J.A., et al., 2012 [65]	Cross-sectional study	India	University, Hospital students	104	54M, 50 F	No	Exclusion criteria: subjects with inflammation, ulcers, trauma, congenital developmental defects, malformation, deformity, surgical scars (e.g., operation for cleft lip), and other abnormalities of lips; subjects with allergy to cosmetics (lipstick)	Tsuchihashi [27]/4	Red lipstick applied to a dry closed mouth. The lips pressed lightly from left to right on white paper supported on a glass plate. The print covered with transparent adhesive tape on white paper. Visualized using a magnifying glass	NA	No/NA	NA
Padmavathi, B. N., et al., 2013 [66]	Cross-sectional study	India	Hospital, volunteers (patients)	250	/	No	Exclusion criteria: subjects with hypersensitivity to cosmetics and lip lesions	Suzuki and Tsuchihashi [12]/6	Dark lipstick, dried on lips, print taken to cellophane tape, then stuck to a paper. Photographed and analyzed on computer	NA	No/Na	None
Peeran, S. W., et al., 2015 [67]	Cross-sectional study	Lybia (subpopulation)	Other	104	37 M, 67 F	No	Exclusion criteria: subjects with gross deformities of lips, known allergy to lipstick materials, and those having active lesions on their lips	Suzuki and Tsuchihashi [12]/4	Dark lipstick, print taken to paper. Visualized with a magnifying lens	NA	No/NA	NA
Popa, M. F., et al., 2013 [68]	Cross-sectional study	Romania	University	100	50 M, 50 F	No	Exclusion criteria: subjects showing inflammations, malformations, surgical scars, or any other lip associated pathology	Suzuki and Tsuchihashi [12]/4	Lipstick, dried on lips, print taken to paper. Visualized with a magnifying lens	NA	No/Na	NA
Prabhu, R.V., et al., 2012 [69]	Cross-sectional study	India	University and Hospital	100	/	No	Exclusion criteria: subjects with inflammation, ulcers, trauma, congenital developmental defects, malformation, deformity, surgical scars, and other abnormalities of lips; subjects with allergy to cosmetics (lipstick)	Suzuki and Tsuchihashi [12]/4	Lip liner + lipstick, dried on lips, print taken separately for upper and lower lip on scotch and cellophane tape, then stuck to a paper. Scanned in grey and analyzed on computer	NA	No NA	None

Table 2. Continued

Study id	Study design	Setting			Participants			Interventions			Outcomes	
		Country	Place/participants	Number	Sex	Used sample size calculator	Inclusion/Exclusion criteria	Classification methodology/number of parts the lips were divided to	Collection/analysis methodology	Inter/intraobserver variability tested?	Results differences between sexes/% of correctly classified	Funding
Prasad, P., et al., 2011 [70]	Cross-sectional study	India	University students	100	50 M, 50 F	No	Inclusion criteria: no lip lesions, no hypersensitivity to lipstick	Suzuki and Tsuchihashi [12]/8	Dark lipstick, dried on lips, print taken to cellophane tape, then stuck to a paper. Visualized with a magnifying lens	NA	NA/NA	NA
Priya, S.P., et al., 2019 [71]	Cross-sectional study	United Arab Emirates	University students	102	52M, 50F	No	Exclusion criteria: individuals having lesions on the lips and/or with known hypersensitivity to lipsticks	Tsuchihashi [27]/8	Latently and superimposed, the lips made on a standard ten-sip porcelain cup within two minutes (without rosy lips) and developed with fingerprint powder. Lipstick applied with a disposable applicator and a strip of clear cellophane tape with the sticky side touching the lip patted to get prints. The prints taken on white paper and photographed with a digital camera	NA	Yes, in some quadrants/NA	NA
Privadharsini, K. I., et al., 2018 [7]	Pilot study	India	University	100	50 M, 50 F	No	Inclusion criteria: lips free from any pathology, normal transition zone between the mucosa and the skin. Exclusion criteria: hypersensitivity to lipsticks and subjects undergoing orthodontics treatment	Tsuchihashi [27]/1 (the entire lip)	Dark lipstick, rubbed, print taken. Visualized with a magnifying lens	Not clear	Yes, in all types (P=0.036) except type I/NA	None
Ragab, A. R., et al., 2013 [72]	Cross-sectional study	Egypt	Other	955	235 M, 720 F	No	Inclusion criteria: lips free from any pathology with normal transition zone between the mucosa and skin	Renaud [40]/6	Lipstick, dried on lips, print taken to paper by different techniques (light pressure, lips rolling), then stuck to a paper. Visualized with a magnifying lens, scanned, and analyzed on computer	NA	No/NA	NA

Table 2. Continued

Study id	Study design	Setting			Participants			Interventions			Outcomes	
		Country	Place/participants	Number	Sex	Used sample size calculator	Inclusion/Exclusion criteria	Classification methodology/number of parts the lips were divided to	Collection/analysis methodology	Inter/intraobserver variability tested?	Results differences between sexes/% of correctly classified	Funding
Ramakrishnan, P., et al., 2015 [73]	Preliminary study	India	University, Hospital	100	50 M, 50 F	No	Exclusion criteria: subjects with any known hypersensitivity to lipsticks and those with congenital or pathological abnormalities, inflammation, or trauma	Suzuki and Tsuchihashi [12]/4	Lipstick, dried on lips, print taken to cellophane tape, then stuck to a paper. Sudan Black B lysochromic reagent placed onto the lip print with a dusting brush. Visualized with a magnifying lens	Yes. Cohen's kappa=0,880, significant agreement	Yes, for types III, IV and V in females' population/NA	NA
Randhawa, K., et al., 2011 [74]	Cross-sectional study	India	University	600	289 M, 311 F	No	Exclusion criteria: individuals with inflammation, trauma, congenital deformity, or any other disease of the lips and any known hypersensitivity to the lipstick	Tsuchihashi [75]/1 (middle part of the lower lip)	Lip prints left on cellophane tape (with fixed and closed lips), print taken to cellophane tape, then stuck on a paper. Visualized with a magnifying lens	NA	Yes, for type I in females and type III in males/NA	NA
Sagar, S., et al., 2019 [76]	Observational study	India	University	200	100 M, 100 F	Yes	Inclusion criteria: subjects with healthy permanent teeth (full complement), ideal dental occlusion, healthy. Exclusion criteria: subjects allergic to cosmetics, with any pathologies (like ulcer, trauma, presence of cleft lip or cleft palate, or abnormalities like malocclusion, dental caries, periodontitis), tobacco users and those with parafunctional habits	Suzuki and Tsuchihashi [12]/1 (middle part of the lower lip)	NA	NA	No/NA	None

Table 2. Continued

Study id	Study design	Setting			Participants		Interventions			Outcomes		
		Country	Place/participants	Number	Sex	Used sample size calculator	Inclusion/Exclusion criteria	Classification methodology/number of parts the lips were divided to	Collection/analysis methodology	Inter/intraobserver variability tested?	Results differences between sexes/% of correctly classified	Funding
Sandhu, H., et al., 2017 [77]	Cross-sectional study	India	University Hospital	1200	540 M, 660 F	Yes	Inclusion criteria: healthy males and females with no systemic, metabolic or, dermatological or, endocrinal disease; individuals who were non-syndromic; individuals born and brought up in Sriranganagar (Northwestern India) and of Indo-Aryan ethnic origin. Exclusion criteria: individuals with missing anterior teeth; individuals with permanent scars on fingers or lips caused by injuries, inflammation, or surgery; individuals with worn fingerprints, extra, webbed, or bandaged fingers; bacterial, viral, or fungal infections affecting lips and hands	Suzuki and Tsuchihashi [12]/6	Dark lipstick, dried on lips, print taken to cellophane tape, then stuck to a paper. Visualized with a magnifying lens	Yes/Kappa=0.8	No/NA	NA
Senthil, K.M., et al., 2017 [78]	Cross-sectional survey	India	Teaching hospital	200	100 M, 100 F	No	Inclusion criteria: Gujarati subjects in age group 18-24 years having healthy lips and fingertips. Exclusion criteria: subjects with a history of skin allergy, trauma, malformation, deformity, surgical scars, active lesion of fingers and lips, composite finger pattern and Type V lip pattern	Suzuki and Tsuchihashi [12]/1 (middle part of the lower lip)	Brown and pink colored non-glossy lipstick dried on lips, print taken to cellophane tape, then stuck to a paper. Visualized with a magnifying lens	NA	No/NA	None

Table 2. Continued

Study id	Study design	Setting			Participants		Interventions			Outcomes		
		Country	Place/participants	Number	Sex	Used sample size calculator	Inclusion/Exclusion criteria	Classification methodology/number of parts the lips were divided to	Collection/analysis methodology	Inter/intraobserver variability tested?	Results differences between sexes/% of correctly classified	Funding
Shah, K.K., et al., 2015 [79]	Cross-sectional study	India	Other	200	100M, 100 F	No	Inclusion criteria: subjects willing to participate, between the age group of 17-25 years and free from scars or lesions on the lips. Exclusion criteria: Subjects not willing to participate, deformities of lips like cleft lip, ulcers, traumatic injury, inflammation, or orthodontic treatment and subjects allergic to the lipstick	NA	Lipstick, lip print taken on paper or cellophane tape	NA	No/NA	NA
Sharma, P., et al., 2009 [80]	Cross-sectional study	India	University	100	50 M, 50 F	No	Inclusion criteria: individuals with no lesions on the lips	Tsuchihashi [27]/1 (middle part of the lower lip)	Dark lipstick, dried on lips, print taken to cellophane tape, then stuck to a paper. Visualized with a magnifying lens	NA	Yes, for some types (I, I', IV and V)/NA	NA
Sharma, R., et al., 2015 [81]	Cross-sectional study	India	University students	201	107 M, 94 F	No	Exclusion criteria: presence of any inflammation, pathology, or developmental anomaly on lips and patients with known hypersensitivity with lipstick	Tsuchihashi [27]/1 (the entire lip)	Dark lipstick, dried on lips, print taken to cellophane tape, then stuck to a paper. Visualized with a magnifying lens	NA	No/NA	None
Sharma, V., et al., 2014 [82]	Clinical study	India	University	200	100 M, 100 F	No	Inclusion criteria: subjects free from any lesions on their lips. Exclusion criteria: subjects with any lip anomalies or any lesions on the lips, those with any known allergy to lipstick, and those who were not willing to participate	Suzuki and Tsuchihashi [12]/2 (upper and lower lips in the midline)	Dark lipstick, dried on lips, print taken to cellophane tape, then stuck to a paper. Visualized with a magnifying lens	NA	Yes, for males types III and IV, and females Types I and I' /78% males, 84% females	NA

Table 2. Continued

Study id	Setting		Participants		Interventions			Outcomes				
	Study design	Country	Place/participants	Number	Sex	Used sample size calculator	Inclusion/Exclusion criteria	Classification methodology/number of parts the lips were divided to	Collection/analysis methodology	Inter/intraobserver variability tested?	Results differences between sexes/% of correctly classified	Funding
Šimović, M., et al., 2016 [9]	Cross-sectional study	Croatia	General population	90	40 M, 50 F	No	Inclusion criteria: individuals with healthy lips and those without any visible signs of previous trauma	Tsuchihashi [27]/1 (the entire lip)	Lips photographed with a centimeter measure with a digital apparatus. Respondents applied red matte lipstick in front of the mirror. The slightly dissolved lip print copied onto white paper; then covered with transparent adhesive tape and digitally photographed	NA	Yes/NA	NA
Singh, J., et al., 2012 [83]	Cross-sectional study	India	University	60	30 M, 30 F	No	Inclusion criteria: lips free from any pathology, normal transition zone between the mucosa and the skin. Exclusion criteria: Individuals with known hypersensitivity to lipstick	Tsuchihashi [27]/4	Dark lipstick, dried on lips, print taken to cellophane tape, then stuck to a paper. Visualized with a magnifying lens	NA	Yes/NA	NA
Sonal, V., et al., 2005 [84]	Cross-sectional study	India	Other	50	20M, 30F	No	Inclusion criteria: individuals having no lesions. Exclusion criteria: individuals with known hypersensitivity to lipsticks	Suzuki [20]/4	A dark colored frosted lipstick, thin bond paper, magnifying lens, pen for labelling details	NA	100% females and 80% males correctly classified	NA
Tandon, A., et al., 2017 [85]	Cross-sectional study	India	Other	100	50 M, 50 F	No	Inclusion criteria: individuals with competent lips. Exclusion criteria: individuals with incompetent lips such as inflammation, trauma, malformation, deformity, surgical scars, and active lesions of lips. Individuals with Type V – unidentified type	Suzuki and Tsuchihashi [12]/4	Dark lipstick, dried on lips, print taken to cellophane tape, then stuck to a paper. Visualized with a magnifying lens	NA	Yes, for type I in females/NA	None
Theradam, T.P., et al., 2020 [86]	Cross-sectional study	India	University	2112	1056 M, 1056 F	No	Inclusion criteria: persons with lip scars, lip lesions, lip congenital deformities, and persons with hypersensitivity to lipstick	Suzuki and Tsuchihashi [12]/4	Dark lipstick, dried on the lips, the print of the upper and lower lips taken separately on cellophane tape, and then glued to the paper. Visualized using a magnifying glass	NA	Yes, for type I' and type I in males and type IV females/92,3% and 96,8% in males, 93,7% in females	None

Table 2. Continued

Study id	Study design	Setting			Participants			Interventions			Outcomes	
		Country	Place/participants	Number	Sex	Used sample size calculator	Inclusion/Exclusion criteria	Classification methodology/number of parts the lips were divided to	Collection/analysis methodology	Inter/intraobserver variability tested?	Results differences between sexes/% of correctly classified	Funding
Thomas, A.J., et al., 2018 [87]	Cross-sectional study	India, Malaysia	Other	128	66 M, 62 F	No	Exclusion criteria: subjects with lip inflammation, ulcers, congenital defects, surgical scars, and history of hypersensitivity reaction to lipsticks	Tsuchihashi [27]/1 (middle part of the lower lip)	Not-glossy red lipstick, imprint placed on paper and covered with cellophane tape. Visualized with magnifying lens	NA	No/NA	Yes
Topczydlo, A., et al., 2018 [88]	Cross-sectional study	Poland	Other	242	76 M, 166 F	No	Exclusion criteria: persons with lip damage or playing brass instruments	Vahanwala [29], Suzuki and Tsuchihashi [12], Topczydlo [88]/4; 1 (middle part of the lower lip); 1 (whole lip print)	No/only the methodology of the analysis (Vahanwala's method, the method based on the micro-section of lower lip print and the author's method)	No	Yes, for their own method/Varies on a method from 44% to 79.8%	NA
Vaishnavi, A., et al., 2019 [89]	Cross-sectional study	India	University	50	25 M, 25 F	No	Inclusion criteria: individuals without any lesions on their lips. Exclusion criteria: individuals sensitive to the lipstick	Vaishnavi [89]/4	Not-glossy dark colored lipstick, print taken to cellophane tape, then stuck to a paper. Visualized with a magnifying lens	NA	Yes, in some quadrants/NA	None
Vats, Y., et al., 2012 [90]	Cross-sectional study	India	Other (subpopulations)	1399	781 M, 618 F	No	Inclusion criteria: lips free from any pathologies such as inflammation, mucocoele, cicatrization, and deformities such as cut mark or lesions	Suzuki and Tsuchihashi [12]/4	Lip balm (wiped after minute) + dark lipstick, dried on lips, print (upper and lower lip separately) taken on cellophane tape, then stuck on a paper. Visualized with a magnifying lens	NA	Yes, for some quadrants and some populations/NA	NA
Verghese, A. J., et al., 2010 [91]	Cross-sectional study	India	University	100	50 M, 50 F	No	Inclusion criteria: subjects aged 25 - 40 years. Exclusion criteria: any disease or deformity of the lips	Tsuchihashi [27]/3	Lipstick was applied on the lips, then cellophane tape was applied on the lips and the prints were taken	NA	No/NA	NA

Table 2. Continued

Study id	Study design	Setting			Participants		Interventions			Outcomes		
		Country	Place/participants	Number	Sex	Used sample size calculator	Inclusion/Exclusion criteria	Classification methodology/number of parts the lips were divided to	Collection/analysis methodology	Inter/intraobserver variability tested?	Results differences between sexes/% of correctly classified	Funding
Verma, P, et al., 2013 [92]	Cross-sectional correlation study	India	University	208	85 M, 123 F	No	Exclusion criteria: subjects undergoing orthodontic treatment, presence of congenital lip abnormalities, inflammation or trauma of lips, hypersensitivity to lipsticks	Suzuki and Tsuchihashi [12]	Red lipstick applied evenly to cleansed lips with a stick, in one stroke. The lip print taken on sticky cellophane tape and taped to white paper. Visualized using a magnifying glass	Yes, two observers/Wilcoxon signed-rank test showing an insignificant inter observer bias	No/NA	None
Yandava, S, et al., 2020 [93]	Observational study	India	University	196	78 M, 118 F	No	Inclusion criteria: subjects free from any active or passive lip lesions. Exclusion criteria: gross deformities of lips like cleft lip, surgical interventions, ulcers, traumatic injuries on lips, cracked lips; known allergy to the lipstick ingredients	Suzuki [20]/4	Dark colored lipstick. Prints taken on a rough surface with center portion of lips dabbed first and then pressed uniformly to either side	NA	Yes, in some quadrants/NA	None
Yendriwat, et al., 2019 [94]	Cross-sectional study	Malaysia, China	University	30	15 M, 15 F	No	Exclusion criteria: subjects with hypersensitivity towards lipstick, pathological conditions on the lips during the study, history of surgery on the lips, and individuals with deformities on the lips post-accident	Tsuchihashi [27]/4	Lip liner + lipstick, print taken to scotch tape, then stuck to a paper. Visualized with a magnifying lens	NA	Yes, $P=0.048$ /NA	None

Table 2. Continued

Study id	Study design	Setting			Participants		Interventions			Outcomes		
		Country	Place/participants	Number	Sex	Used sample size calculator	Inclusion/Exclusion criteria	Classification methodology/number of parts the lips were divided to	Collection/analysis methodology	Inter/intraobserver variability tested?	Results differences between sexes/% of correctly classified	Funding
Zaaba, N. A. A. B., et al., 2020 [95]	Cross-sectional study	Malaysia, India	University	40	20 M, 20 F	No	Inclusion criteria: lips free from any injuries or deformities, no cracked or chapped lips; smooth lips with no other irregularities seen on the lips	Suzuki and Tsuchihashi [12]/1 (the entire lip)	Dark colored lipstick + lipstick applicator, print taken to cellophane tape, then stuck to a paper. Visualized with a magnifying glass	NA	Yes, for type I in females of Indian population, and type III in males of Malaysian population/NA	None
This study	Cross-sectional study	Croatia	Other	176	88 M, 88 F	No	Exclusion criteria: participants allergic to some of the ingredients of lipsticks and/or adhesive tapes and those who have anomalies of the lips, viscerocranium, or teeth	Suzuki and Tsuchihashi [12]/4 (and whole lip)	Dark-colored lipstick applied with a cotton swab to dry lips. Lip prints left on white paper divided into two parts: lip prints with closed mouths and lip prints with partially open mouths. Prints fixed with adhesive tape, scanned in black and white and in color, and analyzed in Microsoft Photos	Yes/NA	No/NA	None

*NA – not declared.

†None – no funding or self-funding.

‡Yes – declared.

For the question, *Were the study subjects and the setting described in detail?* we marked a study as “unclear” with one asterisk if the respondents were not well/clearly selected (sex and/or inclusion and exclusion criteria were not defined). The number of these studies was 11. For example, Ragab, A., et al. [72] had 955 respondents and gave the distribution between sexes, but in this study, most of the participants were female (75%). If the place, institution, sex, and/or age of the study setting and participants characteristics were missing, the study was marked as “unclear” with two asterisks. The number of these studies was 11. The number of other studies marked as “unclear” was eight. The number of studies that did not describe the study subjects and setting in detail was eight. For this criterion, more than the half of the studies (42) described the participants and setting in detail.

For the criteria, *Was the exposure measured in a valid and reliable way?* we marked “yes” only those studies that measured either inter or intraobserver error and reported the results. There were some studies that said that they measured the inter/intra observer error, but they did not report the result, and those were considered as “no”. Only ten studies met this criterion. For the question, *Were objective, standard criteria used for measurement of the condition?* the same criteria as for the previous question was applied; thus, the number of studies that met this criteria is also ten.

The question *Were strategies to deal with confounding factors stated?* was marked NA for all. The reason does not lie in the quality of studies, but rather in the applicability of the mentioned criterion on non-medical studies. As we could not validate studies by this criterion, we have marked all the studies as NA and did not take it into consideration for summary validation of the studies.

For the question, *Were the outcomes measured in a valid and reliable way?* all the studies that did not calculate inter and intraobserver error, and those of them that had significant disagreement were marked as “unclear.” Only nine studies met the criteria.

For the question, *Was appropriate statistical analysis used?* we had two criteria for marking studies as “yes”. “Yes” with no asterisk were those that used only descriptive statistics, and there were 35 of such studies. Additionally, “yes” with one asterisk included those that calculated the inter and intraobserver error, and the number of these studies was 11. The studies that tested the reliability of sex estimation using lip prints were marked with two asterisks, and there were two studies that met this criterion. Thirty-two studies were marked as “unclear,” as these studies yielded only percentages or both percentages and *P* values.

Interobserver/ intraobserver variability: For the critical appraisal, we have calculated the interobserver error. The calculated Cohen’s Kappa between two raters (HE, MP) was as follows: *Were the criteria for inclusion in the sample clearly defined?* 0.832; *Were the study subjects and the setting described in detail?* 0.980, *Was the exposure measured in a valid and reliable way?* 1.000, *Were the outcomes measured in a valid and reliable way?* 1.000, *Was appropriate statistical analysis used?* 0.874. In all the cases, there was an almost perfect agreement.

Overall, only six studies met all the criteria [7, 47, 52, 57, 59, 77]. But none of these studies that observed differences between males and females tested the reliability or accuracy

of sex estimation. In the study of Kapoor, N., et al. [47], 200 people participated, and they found differences in type I in males and type III in females. Moshfeghi, M., et al. [57] did not find differences between sexes among 96 participants. Nagalaxmi, V., et al. [59] found differences in males for type III and females in type I with 60 participants. Priyadharshini, K. I., et al. [7] found differences in all types except type I; the sample consisted of 100 participants. Sandhu et al. [77] tested 1200 participants and did not find differences between sexes. Kinra, M., et al. [52] tested only 40 participants and observed predominance in type I for females and type II for males. As previously stated, a sample size calculator was rarely used, and the only one of these studies that probably met the necessary sample size at 95% confidence interval was the study of Sandhu et al. [77].

The scoping review showed differences in participant and study characteristics and the reliability of sex estimation.

Participant characteristics: In the studies that were analyzed in this research, the number of participants ranged from 20 to 5000, with most of the studies having around 100 participants. There were 33 studies with 100 or less participants, 24 from 101 to 200, 12 from 201 to 500, six from 501 to 1000, and five larger than 1001. Most of the studies were conducted in India, and among European countries only Romanian [68], Polish [88], Portuguese [4], and Croatian [9] (including this study) population samples were analyzed. Only five studies [35, 45, 55, 76, 77] used a sample size calculator during the study preparation, one of which did not calculate the whole population size but only the chosen subpopulation (hospital) population sample size [35]. Two of the studies had no inclusion or exclusion criteria [31, 39]; for the others, the exclusion criteria varied, but most were concentrated on the lack of deformities and illness that could affect the lip grooves.

Study characteristics: Most of the studies used the Suzuki and Tsuchihashi method [12] ($n = 48$; 60%) but not all, and there was no uniformity in the division of the lips into parts. Thus, some of the research only studied one lip (for example, upper) or the lips as a whole, while others divided the lips into two to eight parts. Additionally, not all of them studied all parts of the lip, but some of them chose only one of the lip parts after division for the purposes of their study. Thirty-two of the studies analyzed quadrants (40%), and 26 of them analyzed only one part of the lip or the lips as a whole (32.5%). The most common methods for collection used lipstick (usually dark) and transfer of the print to paper or duct tape. Visualization usually included magnifying glasses or enlarging the photographed print on the computer.

Only ten other studies, in addition to our study, tested inter and/or intraobserver variability [25, 42, 47, 52, 57, 59, 73, 77, 92]. Overall, these studies have a consensus on this variability. Considering the results of the studies, almost an equal number of them showed that there were and were not differences between males and females. Thus, some of the studies confirmed sexual dimorphism – this, for the most part, included only the predominance of a certain pattern in some quadrants in males and females (there were no similarities between the predominance of the quadrant in sexes between males and females). Some of the studies did not find differences in quadrants between males and females.

Sex estimation: Eighteen studies tested the classification rate accuracy for sex estimation, ranging from the lowest 17.4% for males [49] to forensically high 98.6% for whole samples

[86]. Twenty-nine (36.3%) of the studies stated that they did not find differences between males and females, and thirty-four only found differences in some types of furrows and some quadrants (42.5%).

Discussion

The results of both the primary and scoping studies showed that lip prints are not a reliable tool for sex estimation.

The primary study showed that the accuracy of sex estimation was only 55.8%, and it indicated that lip prints should not be used to estimate sex in the Croatian population. However, the variability in lip print patterns within the same person indicates that lip prints are extremely useful for individualization purposes. Besides sexual dimorphism, this study also tested the methodology proposed by Costa et al. [4]. They used four different methods that differed in the way that the lipstick was smeared on the lips as well as the material on which they left the imprint (paper, adhesive tape). In this study, the researchers chose to leave lip prints without rubbing lips on adhesive tape [4]. But several other researchers committed to other methods. Sharma et al. used a method in which dark lipstick was applied in one stroke and left on adhesive tape after two minutes, which was then fixed to white paper [10]. Saraswathi et al. used a method where brown lipstick was applied to previously cleansed lips by first applying it to the central part of the lip and then pushing it evenly to the corners of the lips. Also, as with Sharma et al., the print was left on adhesive tape fixed on white paper [96].

Furthermore, this study also applied a dual research approach to the review of lip print morphology. In the first step, lips were examined by quadrants which showed certain shortcomings of the existing quadrant method. Namely, the lines and furrows on the lips are not uniform in individual quadrants, so depending on which part of each quadrant is observed, there may be discrepancies in the estimation of pattern type among and within researchers. During the implementation of the research, it was noticed that there are large differences between the lateral, central, and medial parts of each quadrant. Therefore, some studies suggested the division of lips into additional quadrants, i.e., a change in the existing methodology [1]. The research of Costa and co-workers concluded, similar to our study, that further developmental work of the methods is extremely important - from the collection of lip prints to the recording methodology, and probably the proposition of any new methodology [4].

The results of the scoping review showed that the predominance of some types of lip prints in males and females was not unified among research, and that a predominant lip print could not be detected. The predominance of one lip print in one sex cannot even be population specific as many of these studies were performed in India, and the homogeneity of evidence is not present there. The lack of connection between lip prints and sex can emerge from several factor such as: the different inclusion and exclusion criteria and the collection methodology. On the other hand, since inter and intraobserver variability was tested ambiguously, we were unable to conclude if the method was objective or subjective and if the scoring methods should be improved. To be fair, we must mention that the stud-

ies that did perform these tests showed good agreement, though we cannot know if these samples were scored by more experienced scorers. The predominance of one type of lip print in males and females is also not uniform and as such does not give us a path to conclude if there is a general predominance of any type of lip print in either sex.

The examined published research papers, as well as the present study, showed that there are several issues that probably contribute to the (un)reliability of results. First, inclusion criteria were usually not uniform; for example, some of the studies just mentioned that they had included healthy individuals, some listed detailed inclusion and exclusion criteria [18, 25, 33, 38, 42], and some gave more detailed exclusion criteria, such as no smoking or lip chewing habits [57]. We cannot be sure if these participants were also excluded in other studies, but probably not all the studies took into consideration all of these parameters. The other issue is sample size and stratification; for most of the studies, the sample size was not calculated, and the distribution of participants regarding sex and age was either small or not proportional. Any sample size calculator results used were vague or non-existent; most of the samples were convenient and not representative of the population. Only five studies used a sample size calculator [35, 45, 55, 76, 77]. As lip print analysis is morphological in nature, it is by definition subjective and dependent on the experience of the researcher, thus the intra and interobserver variability should be tested. Only a minor number of studies tested this variable [25, 42, 47, 52, 57, 59, 73, 77, 92]. In most of these tested studies, the agreement was good or higher; nevertheless, we cannot extrapolate that to the other studies. Although a similar methodology was used to collect and analyze the samples, the number of parts that the lips were divided into varied from one part (whole lip) to various combinations of parts. Thus, some of the results were reported as the predominance of the pattern on the whole lip and some only for one lip part (for example, one quarter). Additionally, in studies where sexual dimorphism was found, it was found usually on one lip part that was not consistent among the studies. As the list of papers consisted mostly of studies from India (62 studies, 77.5%), when analyzing only those samples we did not find population specificity or homogeneity in the distribution of the patterns of lip prints.

The presentation of results was also not uniform. Some studies only reported the frequencies of lip patterns while some gave other descriptive statistics but rarely included the accuracy of sex estimation, which is, as previously explained, the most important parameter in a forensic context. The result of such an unstandardized approach was a large difference between studies ranging from highly dysmorphic lip features to a complete lack of sexual dimorphism. The biggest flaw in most of this research is that they did not offer the accuracy of sex estimation. This information is extremely important for criminal cases, that is, for expert witness testimony. The accuracy of sex estimation is - among the repeatability of methodology, the scientific recognition of methodology, and the existence of validation studies - one of the most important considerations when presenting evidence in court as it can give a judge/jury important information about the accuracy of the findings [97, 98]. Unfortunately, most of the studies presented here did not meet most of these criteria. Here, we could not prove that there was a scientific consensus in any part of the collection or analysis processes, thus studies were reporting diametrically different results. On the other hand, lip prints have shown large variability, and they could probably

be used for individualization. At this time, there is not enough scientific evidence that lip prints could be a reliable tool for sex estimation with the existing approach. Future research should harmonize and evaluate the methodology and only then investigate sexual and population differences of lip prints.

Limitation of the scoping review: The main limitation of this study is that we could not perform deeper data analysis due to differences in study setup and the fact that some of the initially included studies were not available as full texts. There were also various sources of possible bias in these studies which could not be systematically appraised as the reporting of the results and methodologies were not consistently written throughout the studies. It is likely that most of the studies had selection bias, especially when taking into consideration that most of them had a convenience sample. Also, the authors usually did not specify if the researchers were blinded, so there is another potential source of observer bias. There is also an unknown possibility of detection bias. We do not know the researchers' experience in scoring methods (there is no training [8]) since the interrater variability was vaguely tested, if at all.

Novelty of the study: This is the first scoping review made on the criminalistics topic of the sexual dimorphism of lip prints, and it showed the necessity of research in this field.

Recommendations: At this point, we believe that a first step should be a design of the methodological standards for the collection of lip prints and improvement of the scoring methodology. The scoring system should test the subjectivity of the morphological method and give a more detailed explanation about which lip segments and parts should be used. If future research shows that there is a good inter and intraobserver agreement regarding lip morphology, only then should sexual dimorphism be tested. If the lips show sexual dimorphism in several populations (that are well sampled and representative), and if that dimorphism would have a forensic significance (classification rate higher than 95%), then lip prints can be used for sex estimation in criminal procedures.

Conclusions

1. There is no sexual dimorphism in lip prints in the Croatian population.
2. The scoping review showed that the previous studies lack methodology uniformity in collection, lip print gathering, visualization, and interpretation.
3. The scoping review showed that the present methodologies are not reliable.
4. The scoping review showed that the potential rate of error is unknown.
5. Lip prints for sex estimation using available methodologies should not be used as evidence in court.

Provenance: Submitted.

Peer review: Externally peer reviewed.

Received: 5 March 2020 / **Accepted:** 2 September 2021 / **Published online:** 15 October 2021.

Funding: This research received no specific grant from any funding agency in public, commercial or not-for-profit sectors.

Acknowledgements: The authors would like to thank the Dean of the Faculty of Maritime Studies in Split, professor Pero Vidan, PhD as well as the professor Nikola Račić, PhD who helped us in engaging students for lip print collection, as well as to all participants who participated in the study. We are also grateful to the professor Matko Marušić, PhD, whose passion for the evidence-based research moved the boundaries of this research. Tina Poklepović Peričić provided advice on methodology for the scoping review and helped with screening the search results, which was of extreme importance for the success of this research. We would also like to thank Katherine DeHeer who proofread the paper and Ivan Jerković, PhD who read and commented on the final version of the paper. Finally, we would like to thank four anonymous reviewers whose comments gave new insights into the paper and added new value to the paper.

Authorship declaration: MP, HE, SB, MJ, IK, AU and ŽB participated in the development and design of the practical work. MP, IK, AU and ŽB participated in the development and design of the scoping review. MP, HE, IK and ŽB analyzed the data and processed the statistical analysis. MP, HE, SB, MJ, IK; AU and ŽB compiled the concept of work. MP, HE, SB, MJ, IK; AU and ŽB participated in the analysis and interpretation of data, review of work. MP, HE, SB, MJ, IK; AU and ŽB gave final approval of the version for publication.

Competing interests: The authors completed the ICMJE Unified Competing Interest form (available upon request from the corresponding author), and declare no conflicts of interest.

Additional material: This article contains electronic supplementary material which is available for download at st-open.unist.hr.

ORCID

Mihaela Paušić  <https://orcid.org/0000-0003-2357-6662>

Helena Ekštajn  <https://orcid.org/0000-0002-9770-2468>

Ivana Kružić  <https://orcid.org/0000-0002-2285-2189>

Željana Bašić  <https://orcid.org/0000-0002-8327-1978>

References

1. El Domiaty MA, Al-gaidi SA, Elayat AA, Safwat MDE, Galal SA. Morphological patterns of lip prints in Saudi Arabia at Almadinah Almonawarah province. *Forensic SciInt*. 2010;200(1-3).
2. Dhall JK, Kapoor AK. Fingerprint ridge density as a potential forensic anthropological tool for sex identification. *Journal of forensic sciences*. 2016;61(2):424-9.
3. Paulis MG. Estimation of stature from handprint dimensions in Egyptian population. *Journal of forensic and legal medicine*. 2015;34:55-61.
4. Costa VA, Caldas IM. Morphologic patterns of lip prints in a Portuguese population: a preliminary analysis. *Journal of Forensic Sciences*. 2012;57(5):1318-22.
5. Pelin C, Oktem H, Kurkcuoglu A, Olmus H. Lip Print Characteristics in Anatolian Population: Baskent University Sample. *Open Access Library Journal*. 2019;6(1):1-10.
6. Hammad M, Habib H, Bhatti YA, Zia S, Javed F, Abbasi MH, et al. Gender variation of lip prints among the students of Avicenna Medical College, Lahore. *Pak J Med Health Sci*. 2014;8(2):321-3.

7. Priyadharshini KI, Ambika M, Sekar B, Mohanbabu V, Sabarinath B, Pavithra I. Comparison of cheiloscropy, odontometric, and facial index for sex determination in forensic dentistry. *J Forensic Dent Sci.* 2018;10(2):88-91.
8. Moenssens A. Lip prints: Admissibility of comparison results. *Wiley Encyclopedia of Forensic Science.* 2009.
9. Šimovic M, Pavušek I, Muhasilovic S, Vodanovic M. Morphologic patterns of lip prints in a sample of croatian population. *Acta Stomatol Croatica.* 2016;50(2):122-7.
10. Sharma P, Saxena S, Rathod V. Cheiloscropy: The study of lip prints in sex identification. *Journal of forensic Dental sciences.* 2009;1(1):24.
11. Chowdhry A, Kapoor P. Cheiloscropy and Rugoscropy. In: Brkić H, Lessig R, da Silva RHA, Pinchi V, Thevissen P, editors. *Textbook of forensic odonto-stomatology by IOFOS.* Jastrebarsko: Naklada Slap; 2020. p. 235-48.
12. Suzuki K, Tsuchihashi Y. Personal identification by means of lip prints. *J Forensic Med.* 1970;17(2):52-7.
13. Tricco AC, Lillie E, Zarin W, O'Brien KK, Colquhoun H, Levac D, et al. PRISMA extension for scoping reviews (PRISMA-ScR): checklist and explanation. 2018;169(7):467-73.
14. Peters MD, Godfrey CM, Khalil H, McInerney P, Parker D, Soares CB. Guidance for conducting systematic scoping reviews. *International journal of evidence-based healthcare.* 2015;13(3):141-6.
15. Institute JB. Checklist for Analytical Cross Sectional Studies. 2017; Available from: <https://jbi.global/critical-appraisal-tools>.
16. Ahmed S, Salem HE, Fawzy MM. Forensic dissection of lip print as an investigative tool in a mixed Egyptian population. *Alexandria Journal of Medicine.* 2018;54(3):235-9.
17. Ahuja P, Butani TP, Dahiya M. CHEILOSCOPY: A study on lip print patterns among the gujarati population. *Indian Journal of Forensic Medicine & Toxicology.* 2018;12(1):148-53.
18. Alzapur A, Nagothu RS, Nalluri HB. Lip prints-A study of its uniqueness among students of MediCiti Medical College. *Indian journal of clinical anatomy and physiology.* 2017;4(1):68.
19. Amith HV, Ankola AV, Nagesh L. Cheiloscopic Comparison of the Tibetan Refugees in Mundgod and the Population of Belgaum, India. *Indian J Forensic Med Toxicol.* 2012;6(1):9-12.
20. Suzuki K. Forensic odontology and criminal investigation. *Scientific And Educational Bulletin.* 1970;3(1):62-6.
21. Anu V, Lokeswari P, Madhumitra S, Lavanya S, Lavanya C, Madhumitha K. Significance of cheiloscropy and dermatoglyphics in sex determination. *Indian J Forensic Med Toxicol.* 2020;14(3):759-62.
22. Augustine J, Barpande SR, Tupkari JV. Cheiloscropy as an adjunct to forensic indentication: A study of 600 individuals. *J Forensic Odonto-Stomatol.* 2008;26(2):44-52.
23. Aziz MHA, El Dine F, Saeed NMM. Regression equations for sex and population detection using the lip print pattern among Egyptian and Malaysian adult. *Journal of Forensic and Legal Medicine.* 2016;44:103-10.
24. Babladi PI, Satish BNVS, Raghavendra KM, Uzair SH, Reddy M. Lip prints-effective tool of identification and sex determination. *Indian J Forensic Med Toxicol.* 2012;6(1):74-5.
25. Badiye A, Kapoor N. Morphologic variations of lip-print patterns in a Central Indian population: A preliminary study. *Med Sci Law.* 2016;56(3):200-4.
26. Bai JKS, Prakash AR, Reddy AVS, Rajinikanth M, Sreenath S, Kumar Reddy KVK. Correlative study on lip prints, fingerprints, and mandibular intercanine distance for gender determination. *J Forensic Dent Sci.* 2018;10(3):143-50.
27. Tsuchihashi Y. Studies on personal identification by means of lip prints. *Forensic Science.* 1974;3:233-48.
28. Ballur MS, Murgod P, Dayananda R. A study of lip prints among Kerala population. *Indian J Forensic Med Toxicol.* 2016;10(1):122-5.
29. Vahanwala SP, Parekh BK. Study of lip prints as an aid to forensic methodology. *J Forensic Med Toxicol.* 2000;17(1):12-8.
30. Bansal AK, Doshi S, Bansal P, Patel R, Barai PH. Cheiloscropy: A lip print study. *Indian J Forensic Med Toxicol.* 2019;13(2):35-9.

31. Bansal N, Sheikh S, Bansal R, Pallagati S. Correlation between lip prints and finger prints in sex determination and pattern predominance in 5000 subjects. *J Forensic Odonto-Stomatol.* 2014;31(1):8-14.
32. Basheer S, Gopinath D, Shameena PM, Sudha S, Lakshmi JD, Litha. Correlation of lip patterns, gender, and blood group in North Kerala population: A study of over 800 individuals. *J Forensic Dent Sci.* 2017;9(2):73-7.
33. Bharat Kumar ED. Study of lip prints as a tool for identification: An assessment on 200 subjects in south India. *Indian J Forensic Med Toxicol.* 2017;11(2):31-5.
34. Bharathi S, Thenmozhi MS. Cheiloscopy – Lip print, an determination of sex and individual. *J Pharm Sci Res.* 2015;7(6):330-3.
35. Borase AP, Shaikh S, Mohatta A. A Study of Lip Prints among North Maharashtra Population. *J Adv Oral Res.* 2016;7(3):20-5.
36. Chaudhari SH, Sahay S, Kawanpure H, Mugadlimath A, Sane M, Gathe B. A study of cheiloscopic patterns in Chhattisgarh population. *Indian J Forensic Med Toxicol.* 2017;11(2):119-23.
37. Dey A, Chanak M, Das K, Mukherjee K, Bose K. Variation in lip print pattern between two ethnic groups, Oraon tribals and Bengalee Hindus, residing in West Bengal, India. *Anthropol Rev.* 2019;82(4):405-15.
38. Divyadharsini V, Jayanth Kumar V. Analysing cheiloscopic pattern and mandibular canine index for gender determination. *Res J Pharm Technol.* 2019;12(1):254-8.
39. Dixit A, Jain U, Ahuja P. Cheiloscopy aiding in sex and race determination: A pilot study. *Indian J Forensic Med Toxicol.* 2019;13(2):103-7.
40. Renaud M. *L'identification chéiloscopique en médecine légale: Editions Médicales et Universitaires; 1973.*
41. Gouda S, Surender Rao M. Morphological study of lip print pattern among medical students: An anthropological study. *Med-Leg Update.* 2017;17(1):213-6.
42. Gupta S, Gupt K, Gupta OP, Verma AK. Evaluation of the degree of agreement in identifying lip prints and palatal rugae by three independent observers and valuation of there dependability in sex determination. *Indian J Forensic Med Toxicol.* 2014;8(1):214-20.
43. Gupta S, Gupta K, Gupta OP. A study of morphological patterns of lip prints in relation to gender of North Indian population. *J Oral Biol Craniofac Res.* 2011;1(1):12-6.
44. Herrera LM, Fernandes CMdS, Serra MdC. Evaluation of Lip Prints on Different Supports Using a Batch Image Processing Algorithm and Image Superimposition. *Journal of Forensic Sciences.* 2018;63(1):122-9.
45. Ishaq N, Malik AR, Ahmad Z, Ullah SE. Determination of Sex by Cheiloscopy as an Aid to Establish Personal Identity. *Ann King Edward Med Univ Lahore Pak.* 2018;24(1).
46. Jeergal PA, Pandit S, Desai D, Surekha R, Jeergal VA. Morphological patterns of lip prints in Mangaloreans based on Suzuki and Tsuchihashi classification. *J.* 2016;20(2):320-7.
47. Kapoor N, Badiye A. A study of distribution, sex differences and stability of lip print patterns in an Indian population. *Saudi J Biol Sci.* 2017;24(6):1149-54.
48. Karki RK. Lip prints-an identification aid. *Kathmandu Univ Med J.* 2012;10(38):55-7.
49. Kaul R, Padmashree SM, Shilpa PS, Sultana N, Bhat S. Cheiloscopic patterns in Indian population and their efficacy in sex determination: A randomized cross-sectional study. *J Forensic Dent Sci.* 2015;7(2):101-6.
50. Kautilya DV, Bodkha P, Rajamohaw N. Efficacy of Cheiloscopy in Determination of Sex Among South Indians. *Journal of Clinical and Diagnostic Research.* 2013;7(10):2193-6.
51. Kelasi PSA, Gheena S. The study of lip prints in relation to gender and facial form among third year students in a dental institution. *Indian J Forensic Med Toxicol.* 2019;13(4):47-52.
52. Kinra M, Ramalingam K, Sethuraman S, Rehman F, Lalawat G, Pandey AJJoD. Cheiloscopy for sex determination: A study. 2014;4(1):48-51.
53. Koneru A, Surekha R, Nellithady GS, Vanishree M, Ramesh D, Patil RS. Comparison of lip prints in two different populations of India: Reflections based on a preliminary examination. *J Forensic Dent Sci.* 2013;5(1):11-5.
54. Krishnan RP, Thangavelu R, Rathnavelu V, Narasimhan M. Gender determination: Role of lip prints, finger prints and mandibular canine index. *Experimental Ther.* 2016;11(6):2329-32.

55. Manikya S, Sureka V, Prasanna MD, Ealla K, Reddy S, Bindu PS. Comparison of Cheiloscopy and Rugoscopy in Karnataka, Kerala, and Manipuri Population. *Journal of International Society of Preventive & Community Dentistry*. 2018;8(5):439-45.
56. Mantilla Hernández JC, Otero Pabón YN, Martínez Paredes JF. Sex determination by cheiloscopy in Santander, Colombia: A tool for forensic pathology. First study. *Rev Esp Med Leg*. 2015;41(3):111-6.
57. Moshfeghi M, Beglou A, Mortazavi H, Bahrololumi N. Morphological patterns of lip prints in an Iranian population. *Journal of Clinical & Experimental Dentistry*. 2016;8(5):e550-e5.
58. Multani S, Thombre V, Thombre A, Surana P. Assessment of lip print patterns and its use for personal identification among the populations of Rajnandgaon, Chhattisgarh, India. *Journal of International Society of Preventive & Community Dentistry*. 2014;4(3):170-4.
59. V N, Ugrappa S, M NJ, Ch L, Maloth KN, Kodangal S. Cheiloscopy, Palatoscopy and Odontometrics in Sex Prediction and Dis-crimination - a Comparative Study. *Open Dent J*. 2014;8:269-79.
60. Nagasupriya A, Dhanapal R, Reena K, Saraswathi T, Ramachandran C. Patterns - "A crime solver". *J Forensic Dent Sci*. 2011;3(1):3-7.
61. Santos M. Queiloscopy: A supplementary stomatological means of identification. *International Microform J Legal Medicine*. 1967;2.
62. Nagpal B, Hegde U, Sreeshyla HS, Arun M. Comparative evaluation of lip prints among Indian and Malaysian students. *J Indian Acad Forensic Med*. 2015;37(2):131-4.
63. Naik R, Ahmed Mujib BR, Telagi N, Hallur J. Comparative analysis of lip with thumbprints: An identification tool in personal authentication. *Journal of oral and maxillofacial pathology : JOMFP*. 2017;21(1):171-5. Epub 2017/05/10.
64. Negi A, Negi A. The connecting link! Lip prints and fingerprints. *J Forensic Dent Sci*. 2016;8(3):177.
65. Oliveira JA, Rabello PM, Fernandes LCC. A cheiloscopy study of undergraduate dental students. *Pesqui Bras Odontopediatria Clin Integr*. 2012;12(4):521-8.
66. Padmavathi BN, Makkad RS, Rajan SY, Kolli GK. Gender determination using cheiloscopy. *J Forensic Dent Sci*. 2013;5(2):123-8.
67. Peeran SW, Kumar PGN, Abdalla KA, Azaruk FAA, Manipady S, Alsaid FM. A study of lip print patterns among adults of Sebha city, Libya. *J Forensic Dent Sci*. 2015;7(1):67-70.
68. Popa MF, Ștefănescu C, Corici PD. Medical-legal identification methods with the aid of cheiloscopy. *Rom J Leg Med*. 2013;21(3):215-8.
69. Prabhu RV, Dinkar A, Prabhu V. A study of lip print pattern in Goan dental students - A digital approach. *J Forensic Leg Med*. 2012;19(7):390-5.
70. Prasad P, Vanishree. A comparison of lip prints between Aryans-Dravidians and Mongols. *Indian J Dent Res*. 2011;22(5):664-8.
71. Priya SP, Salem AA, Almadhani A, Thomas S, Bhaskar S, Alkhalidi CKH, et al. Study on lip prints-to estimate the reliability as a personal identification method. *World J Dent*. 2019;10(3):186-91.
72. Ragab AR, El-Dakroory SAEA, Rahman RHA. Characteristic patterns of lip prints in Egyptian population sample at Dakahlia Governorate. *Int J Leg Med*. 2013;127(2):521-7.
73. Ramakrishnan P, Bahirwani S, Valambath S. Assessment of cheiloscopy in sex determination using lysochrome - A preliminary study. *J Forensic Dent Sci*. 2015;7(3):195-200.
74. Randhawa K, Narang RS, Arora PC. Study of the effect of age changes on lip print pattern and its reliability in sex determination. *J Forensic Odonto-Stomatol*. 2011;29(2):45-51.
75. Suzuki K, Suzuki H, Tsuchihashi Y. On the female lips and rouge. *Shikwa Gakuho*. 1967;67:471.
76. Sagar S, Bhuyan SK, Misra SR. Evaluation of the utility of cheiloscopy, rugoscopy, dactyloscopy and odonto-morphometry for human identification and gender determination in an eastern indian population: An observational study. *Indian J Forensic Med Toxicol*. 2019;13(4):1902-7.
77. Sandhu H, Verma P, Padda S, Raj SS. Frequency and correlation of lip prints, fingerprints and ABO blood groups in population of Sriganganagar District, Rajasthan. *Acta Med*. 2017;46(2):105-15.
78. Senthil Kumaran M, Bastia BK, Kumar L, Patel SH, Jr. Correlation between fingerprint and lip print pattern in Gujarati population. *Med-Leg Update*. 2017;17(1):217-21.

79. Shah KK, Jayaraj G. Cheiloscopy for Sex Determination Among Individuals Aged 17-25 Years. *J Pharm Sci Res.* 2015;7(9):731-5.
80. Sharma P, Saxena S, Rathod V. Comparative reliability of cheiloscopy and palatoscopy in human identification. *Indian J Dent Res.* 2009;20(4):453-7.
81. Sharma R, Sharma K, Preethi N, Degra H, Rajmani H. Cheiloscopy: A Study of Morphological patterns of Lip Prints in Rajasthani population. *Journal of Research in Medical and Dental Science.* 2015;3(1):35-8.
82. Sharma V, Ingle NA, Kaur N, Yadav P. Identification of sex using lip prints : A clinical study. *Journal of International Society of Preventive & Community Dentistry.* 2014;4(Suppl 3):S173-7.
83. Singh J, Gupta KD, Sardana V, Balappanavar AY, Malhotra G. Sex determination using cheiloscopy and mandibular canine index as a tool in forensic dentistry. *J Forensic Dent Sci.* 2012;4(2):70-4.
84. Sonal V, Nayak CD, Pagare SS. Study of lip-prints as aid for sex determination. *Med-Leg Update.* 2005;5(3):93-8.
85. Tandon A, Srivastava A, Jaiswal R, Patidar M, Khare A. Estimation of gender using cheiloscopy and dermatoglyphics. *Natl.* 2017;8(2):102-5.
86. Thermadam TP, Chatra L, Ahsan A. Cheiloscopy in gender determination: A study on 2112 individuals. *Journal of Family Medicine & Primary Care.* 2020;9(3):1386-90.
87. Thomas AJ, Padubidri JR, Rao SJ, Udupa R, Suresh Kumar Shetty B, Pavanchand Shetty H, et al. Morphology of lip print patterns among Indian and Malaysian population- a tool for racial and gender identification. *Indian J Forensic Med Toxicol.* 2018;12(2):272-7.
88. Topczydło A, Borysławski K, Nowakowski D. A comparison of sex identification methods based on lip furrow pattern. *Anthropol Rev.* 2018;81(1):45-52.
89. Vaishnavi A, Sangeetha S, Premavathy D. Lip prints - A study of its uniqueness, prevalence, and gender significance. *Drug Invent Today.* 2019;12(4):781-4.
90. Vats Y, Dhall JK, Kapoor A. Gender variation in morphological patterns of lip prints among some north Indian populations. *J Forensic Dent Sci.* 2012;4(1):19-23.
91. Verghese AJ, Somasekar M, Umesh Babu RJJolAoFM. A study on lip print types among the people of Kerala. 2010;32(1):6-7.
92. Verma P, Sachdeva SK, Verma KG, Saharan S, Sachdeva K. Correlation of Lip Prints with Gender, ABO Blood Groups and Intercommissural Distance. *N A J Med Sci (Hamilt).* 2013;5(7):427-31.
93. Yandava S, Jayasurya Prasad Babu V, Surendar J. Cheiloscopy – a tool of identification. *Indian J Forensic Med Toxicol.* 2020;14(3):710-6.
94. Yendriwati, Joe JW, Fitri AR. Lip Print as a Method for Forensic Identification on Malaysian with Chinese Ethnicity. *J Evol Med Dent Sci-JEMDS.* 2019;8(37):2831-40.
95. Zaaba NAAB, Gheena S. Cheiloscopy: The study of lip prints in sex identification between Indian and Malaysian population. *Indian J Forensic Med Toxicol.* 2020;14(1):356-61.
96. Saraswathi T, Mishra G, Ranganathan K. Study of lip prints. *Journal of forensic dental sciences.* 2009;1(1):28.
97. Daubert Standard. In: Li SZ, Jain A, editors. *Encyclopedia of Biometrics.* Boston, MA: Springer US; 2009. p. 209-10.
98. States FvU. 293 F. 1013 (DC Cir. 1923). 1923.