

# Ankylosis of knee joint in human skeletal remains from Istria, case report from St. Teodor (15th-18th centuries)

---

Pamić, Siniša; Šarkić, Nataša; Kuhtić, Ivana; Percen, Tihomir; Krešić, Elvira; Linić, Magdalena; Erjavec, Igor; Bašić, Željana

Source / Izvornik: **Journal of bioanthropology**, 2022, 2, 22 - 28

Journal article, Published version

Rad u časopisu, Objavljena verzija rada (izdavačev PDF)

<https://doi.org/10.54062/jb.2.1.8>

Permanent link / Trajna poveznica: <https://um.nsk.hr/um:nbn:hr:227:221806>

Rights / Prava: [Attribution 4.0 International](#)/[Imenovanje 4.0 međunarodna](#)

Download date / Datum preuzimanja: **2025-03-04**

SVEUČILIŠTE  
U  
SPLITU



SVEUČILIŠNI  
ODJEL ZA  
FORENZIČNE  
ZNANOSTI

Repository / Repozitorij:

[Repository of University Department for Forensic Sciences](#)



UNIVERSITY OF SPLIT

  
dabar  
DIGITALNI AKADEMSKI ARHIVI I REPOZITORIJI

## Ankylosis of knee joint in human skeletal remains from Istria, case report from St. Teodor (15th-18th centuries)

Elvira Krešić<sup>1</sup>, Magdalena Linić<sup>2</sup>, Igor Erjavec<sup>3</sup>, Željana Bašić<sup>4</sup>, Siniša Pamić<sup>5</sup>, Tihomir Percan<sup>5</sup> †, Ivana Kuhtić<sup>1</sup>, Nataša Šarkić<sup>6</sup>

<sup>1</sup>University Hospital Center "Zagreb", Department of Diagnostic and Interventional Radiology

<sup>2</sup>University of Bradford

<sup>3</sup>University of Zagreb, School of Medicine, Center for Reproductive and Regenerative Medicine, Laboratory for Mineralized Tissue

<sup>4</sup>University of Split, University Department of Forensic Sciences

<sup>5</sup>Croatian Conservation Institute

<sup>6</sup>Aita Bioarchaeology

\* Corresponding author: [magdalena.linic@gmail.com](mailto:magdalena.linic@gmail.com)

Received September 26<sup>th</sup>, 2022

Accepted for publication December 8<sup>th</sup>, 2022

Online First December 13<sup>th</sup>, 2022

**Keywords:** knee, ankylosis, CT, paleoradiology, Croatia.

### Abstract

**Objective:** To present a case of knee joint ankylosis in human skeletal remains found in Istria, Croatia.

**Materials and methods:** A fused knee joint was found at archeological site St Teodor. We analyzed the knee changes using macroscopic observation, using digital radiography and computed tomography.

**Results:** Macroscopic analysis and both digital radiography and computed tomography imaging show knee ankylosis with cortical thickening.

**Conclusion:** Knee ankylosis with cortical thickening suggests that the person still used the leg despite the disability.

### Introduction

X-ray scanning of a child mummy in AD 1896 in Frankfurt Museum, only three months after the invention of the X-ray, is considered to be a birthdate of paleoradiology (Rühli et al., 2004; Chhem and Brothwell, 2007; Zesch et al., 2016). However, the name was coined by Notman almost a century later; in AD 1987 when frozen sailors from the Franklin expedition were studied (Notman et al., 1987). Dragutin Gorjanović Kramberger, a famous Croatian paleontologist was the first to scan fossilized remains of Neanderthal man from Krapina in 1901 in the Sisters of Mercy Hospital in Zagreb (Gorjanović-Kramberger, 1899). Since then X-ray has remained a golden standard

in paleoradiology, particularly for bony structures as it is easily available to archeologists and bioanthropologists (Chhem and Brothwell, 2007). On the other hand, computed tomography (CT) provides superior contrast and spatial resolution and has the capacity to remove superimposed embalming materials from images of internal structures, which is very important in the study of mummies (Braunstein et al., 1988). Ankylosis is a condition when a complete or partial fixation of a joint, by an osseous or fibrous union of the bones, is caused by disease or injury (Roberts & Manchester, 2010).

We present a case report of an ankylosed knee joint, found in St. Teodor graveyard, Istria, Croatia (15th-18th



Figure 1. Excavations carried out in AD 2019 on grave 5

century) scanned on X-ray and CT, and provide an overview of 3D reconstructions on CT.

### Materials and Methods

Digital radiography is a fundamental imaging method in the skeletal analysis of human remains. It is a widely accessible imaging method for archeologists and bioanthropologists. In clinical medicine and scientific study of mummies, CT is essential for obtaining information about the soft tissues and internal body cavities, or in this case, for the quantitative evaluation of the cortical bone thickness. The benefits of CT include the capacity to remove superimposed embalming material from images of internal structures and also the superior contrast and spatial resolution (in comparison with X-ray). A possible limiting factor for the use of CT in paleoradiology can be its availability to archeologists and bioanthropologists.

The church of St. Teodor, located on the border of the municipalities of Rakalj and Krnica (Istria, Croatia) was

first mentioned in AD 690. In the sources known so far, it was not mentioned again until the 17th century. The church was abandoned in the 19th century, after which it quickly decayed, and the sacred inventory was moved to the parish church of St. Blaža in Vodnjan. (Milotić, 2010). Since AD 2018, archaeological research has been carried out by the Croatian Conservation Institute.

During the excavations carried out in AD 2019 in grave 5, (Figure 1) which is located in the western part of the church, among many dislocated bones, a part of the upper and lower right leg (femur and tibia), completely fused, was discovered (Figure 2). Based on coins and jewelry found in that grave, it is most likely that grave 5 dates to the 15th-18th century.

The fused right knee has been scanned in University Hospital Centre Zagreb on Axiom Aristos MX (Siemens, Erlangen, Germany) X-ray unit and Multidetector computerized tomography (MDCT). CT scans were obtained using a Siemens Sensation 16 unit (Siemens, Erlangen, Germany) with the following scan

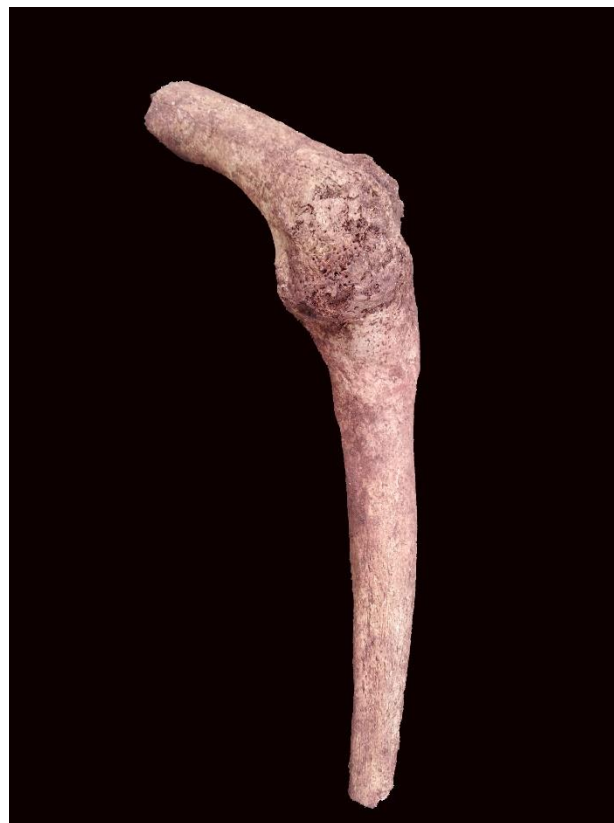

Figure 2. Part of the upper and lower right leg (femur and tibia), completely fused

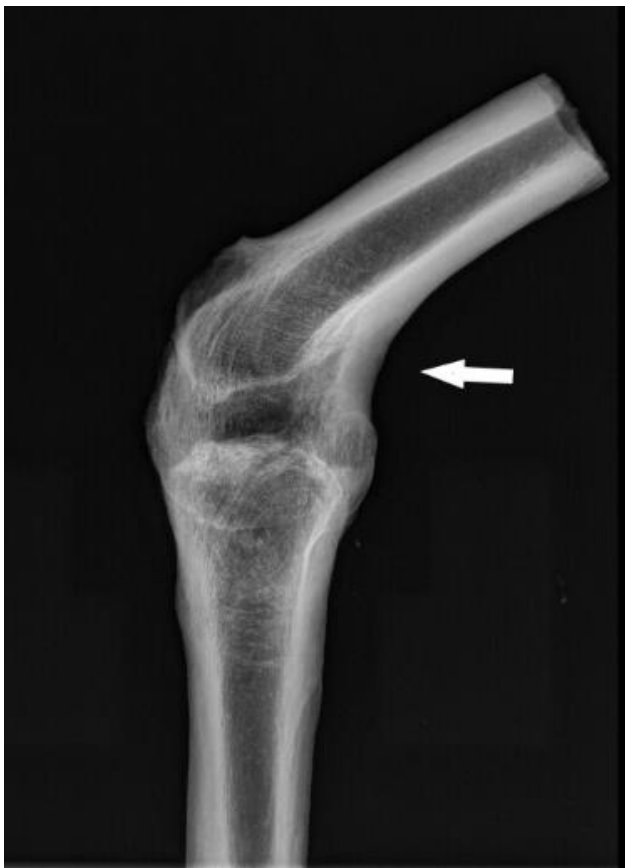

Figure 3. Part of the upper and lower right leg (femur and tibia), completely fused x-ray

parameters;  $16 \times 0.75$  mm collimation, 130 KVP, and 300 mAs with a field of view (202 mm). Post-processing (3D volume rendering technique - VRT) and multiplanar reconstructions (MPR) were done using imaging processing software (Horos MD v. 8.1.5. Pixmeo Software, Geneva, Switzerland).

## Results

Part of a right femur and tibia were preserved with a partially ankylosed knee joint in the lateral compartment. The knee was bent in a flexed position at  $45^\circ$  degrees. Unfortunately, due to the large number of individuals buried in this grave (Minimal Number of Individuals was 7), as well as it was the case of the commingled remains, it was not possible to determine whether any other bones from this assemblage belonged to the individual who had this pathological change, and consequently, neither the sex nor age at death could be estimated. Based on closed epiphyses and cortical thickness, we concluded that the knee

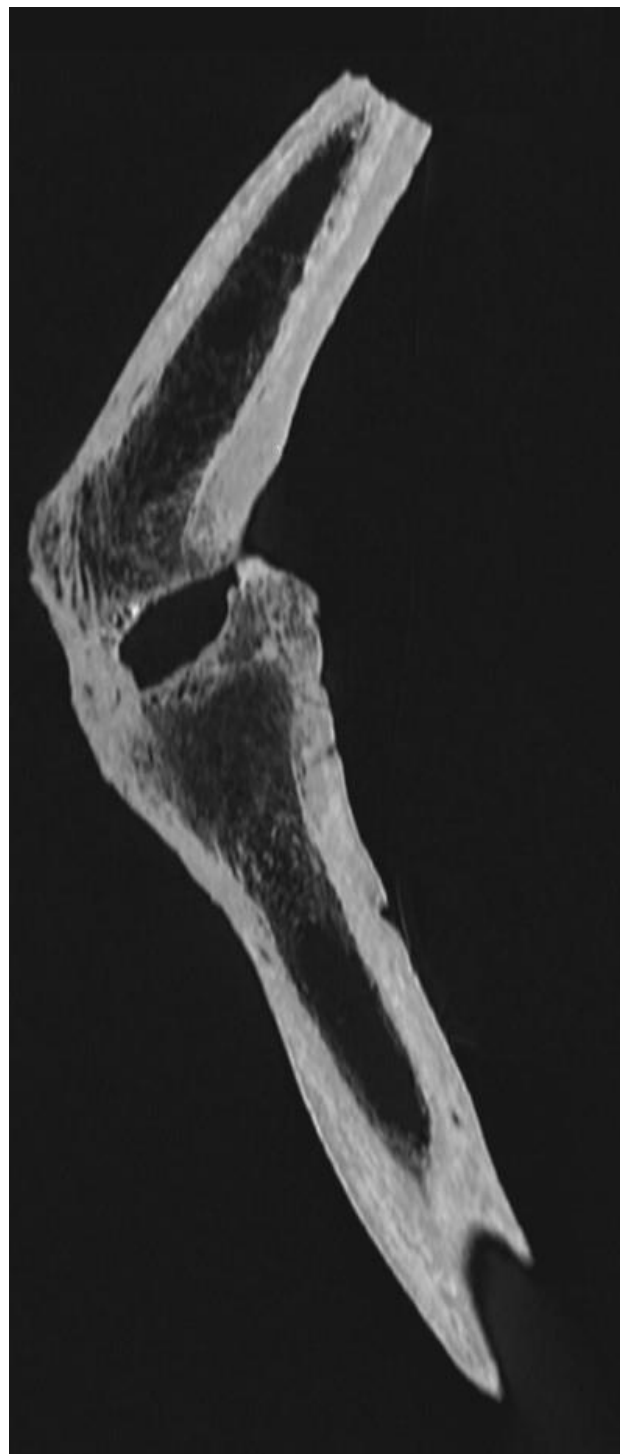


Figure 4. Part of the upper and lower right leg (femur and tibia), completely fused CT imaging

belonged to an adult individual. Macroscopic analysis and both x-ray (Figure 3) and CT imaging (Figures 4 and 5) showed tibiofemoral joint fusion with cortical thickening up to 13 mm and normal trabecular bone architecture.

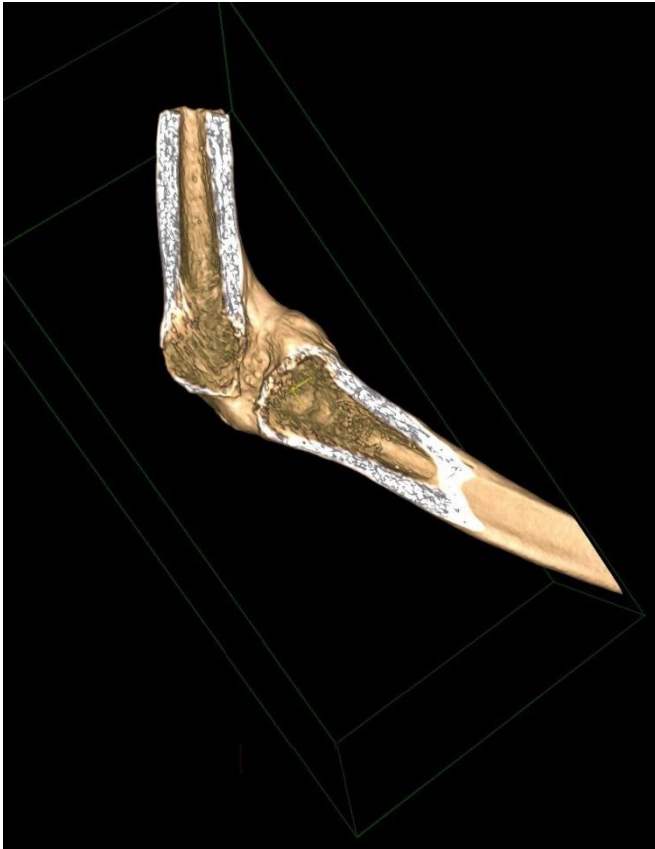


Figure 5. Part of the upper and lower right leg (femur and tibia), completely fused CT imaging

## Discussion

Despite the condition of the knee joint, the individual has used the leg throughout life. The absence of osteoporosis and thinning of the cortical bone support this statement. (Brickley et al., 2020).

Nowadays in Western societies ankylosis of the knee is rather a rare condition as diseases are treated as early as possible, but in the past when treatments were not

so widely available this was not the case. Still, ankylosis of limb joints is a rarely described alteration in paleopathological literature (Ortner, 2003; Roberts & Manchester, 2010). Lately, ankylosis of a knee joint from Medieval London has been reported (Redfern & Austin, 2020). Their re-analysis of a female skeleton with knee joint fusion suggests that the ankylosis was most likely formed due to a congenital condition, but non-adult trauma and osteoarthritic changes were discussed as well. In our case, no other visible signs of fracture are detectable, although they could be hidden in medial parts of the knee which are missing. Several underlying conditions could cause the ankylosis of a knee joint and should be taken into consideration for a differential diagnosis.

One of the outcomes of untreated rheumatoid arthritis (RA) could be ankylosis of the limb. The most prominent feature of rheumatoid arthritis is polyarthritis which is manifested with pain and swelling of the feet, wrists, hands, and knees. Individuals with longstanding, inadequately treated RA develop joint damage and deformities. Characteristic deformities for RA are ulnar deviation, swan neck, and boutonniere deformities of the hands, and flexion contractures of the knees and elbows. Those classic late-stage deformities are less common in the modern age due to improved treatment options (Sparks, 2019).

Although there is no agreement on the antiquity of the RA, the first modern description is found in the dissertation of Augustin Jacob Landré-Beauvais from AD 1800 (Entezami et al., 2011). For the cases of RA before AD 1800, we present the evidence of its existence in chronological order (Table 1 and Table 2) (Aceves-Avila

Table 1. The most convincing descriptions of chronic polyarthritis before 1800.

Source	Place	Time
Caraka Samhita	India	500 BC–AD 100
Scribonius Largus	Rome	Circa 100 BC
Michael Psellus	Rome	Circa AD 1000
Alonso López de Hinojosos	México	AD 1578
Thomas Sydenham	England	AD 1676
William Heberden the Elder	England	AD 1710–1801
Jon Pétursson	Iceland	AD 1782

Table 2. Pictorial evidence of the existence of chronic symmetric polyarthritis before the 19th century. The artistic representations are from Europe.

Painting	Artist	Year
The Temptation of St. Anthony	Unknown	1500–1670
The Donators	Jan Gossaert	Possibly 1530
Portrait of Siebrandus Sixtius	Unknown	1538–1631
Various paintings	Peter Paul Rubens	1577–1640
The Painter's Family	Jacobo Jordaen	1593–1678

et al., 2001). In Table 2 there is artistic evidence and we always have to be careful when analyzing art as it is always questioned to what extent the created painting is a realistic review or just a representation of the style (Čavka et al., 2010; Rühli et al., 2016; Bianucci et al., 2020).

In our case what makes RA unlikely as a cause of ankylosis is a lack of bone erosions. RA causes chronic inflammation which leads to peri-inflammatory bone lesions (erosions). In other words, the damage to the cortical bone with the destruction of the barrier between the bone marrow compartment and the extra-skeletal tissue (Lorenzo et al., 2015).

Another possible cause of knee joint ankylosis is tuberculosis (TB). The oldest cases of human tuberculosis date from 7000 BC in the site of Atlit Yam (Eastern Mediterranean, Israel). Remains of an immature individual and an adult female presented paleopathological evidence of TB, and were confirmed by aDNA analyses and lipid biomarkers (Hershkovitz et al., 2008). Among the earliest cases of TB in skeletal evidence in Europe, there are cases of Pott's disease in two individuals from the Early Neolithic (5400-4800 BC) from three sites in Germany (Halberstadt, Derenburg and Karsdorf) (Nicklisch et al., 2012).

As for skeletal manifestations of TB, the most affected site is the spine. Vertebral bodies are affected by lytic lesions resulting in ankylosis, body collapse and kyphosis (Pott's disease). Articular lesions are second in frequency. The large and medium-sized joints are involved preferentially, the hip and the knee particularly. It is rare for TB to affect more than one joint. TB presents with synovitis (which includes synovial hypertrophy and effusion), marginal erosions

and juxta-articular osteopenia. Untreated TB can progress to joint ankylosis (Chapman et al., 1979). As mentioned before, in our case there are no visible erosions, so TB is probably not a cause of knee ankylosis.

Untreated syphilitic arthritis can also lead to joint ankylosis. Syphilis, according to most scientists, spread to Europe immediately after the discovery of America (Naranjo, 1994). Many artists became victims of this highly contagious disease, some of them are Franz Schubert, Robert Schumann, Bedrich Smetana, Ernst Theodor A. Hoffmann, Arthur Schopenhauer, Charles Baudelaire, Gustave Flaubert, Edouard Manet, Friedrich W. Nietzsche, Paul Gauguin, etc. (Rietschel et al., 2004). Neuropathic arthropathy of the Charcot joint was first described by Charcot as an arthritic sequela of neurosyphilis (Badazadeh et al., 2010). Neurosyphilis or tertiary syphilis often affects large weight-bearing joints such as the knee. Changes in the affected joint include destruction of articular surfaces, joint debris (loose bodies), dislocation and deformity (Pinzur, 2000).

Today we know that Charcot neuropathic osteoarthropathy is seen in individuals with various peripheral neuropathies, such as diabetes, trauma, and metabolic abnormalities (Harris & Violand, 2022). In the modern age, diabetes mellitus has taken over as the major cause of the Charcot joint (Sella & Barrette, 1999; Parvizi et al., 2003). However, diabetes is more likely to affect the foot and ankle (Lee et al., 2003). Midfoot collapse, described as a "rocker-bottom" foot is the hallmark deformity associated with this condition (Rogers et al., 2011).

As for the antiquity of diabetes mellitus, Aretaeus of Cappadocia AD 100 gave the first accurate description

of the disease, and introduced the term 'diabetes' (from the Greek diabainein which means passing through; a large discharge of urine) (King & Rubin, 2003). Dupras et al. (2010) described the earliest case of diabetes mellitus in skeletal remains from Dayr al-Barsha, Egypt dated to ca. 2050-1911 BC.

Recently, the so-called Medici syndrome has raised much attention in the history of medicine. The Medici, a famous family from Florence, ruled the city for most of the period from the 1430s to the 1730s. Given their wealth, political power, often poor health and the fact that they were patrons of arts, the Medici rulers and their relatives have attracted the attention of biomedical researchers as well as historians. Males in the Medici family suffered from a triple pathology of stenotic spinal ankylosis, recurrent peripheral joint disease and erythematous skin disease. Authors mention knee ankylosis as a final complication (sequel) of peripheral joint disease. (Lippi et al., 2014). Although this would be highly improbable, as only part of a right femur and tibia with a partly ankylosed knee joint was available for analysis, the Medici syndrome, as well as Charcot neuropathy, should be included in the differential diagnosis.

## Conclusion

Our case shows an adult individual with knee joint ankylosis. Based on bone morphology and cortical thickness we can conclude with great certainty that this individual has used the leg in everyday life despite the disability caused by a fusion of the knee joint.

## References

Aceves-Avila, F.J., Medina, F. & Fraga, A. (2001) The Antiquity of Rheumatoid Arthritis: A Reappraisal. *J Rheumatol* 28(4), 751–7.

Babazadeh, S., Stoney, J.D., Lim, K., & Choong, P.F.M. (2010) Arthroplasty of a Charcot knee. *Orthop Rev (Pavia)* 2(2), e17. <https://doi.org/10.4081/or.2010.e17>.

Bianucci, R., Kirkpatrick, C.L., Perciaccante, A., Galassim F.M., Lippim D., Appenzeller, O., & Nerlichm A.G. (2020) A case of congenital Horner syndrome from the 16th century. *Lancet Neurol* 19(8), 646-647. [https://doi.org/10.1016/S1474-4422\(20\)30214-3](https://doi.org/10.1016/S1474-4422(20)30214-3)

Braunstein, E.M., White, S.J., Russell, W., & Harris, J.E. (1988) Paleoradiologic evaluation of the Egyptian royal mummies. *Skeletal Radiol* 17, 348–352. <https://doi.org/10.1007/BF00367181>

Brickley, M., Ives, R., & Mays, S. (2020) *The bioarchaeology of metabolic bone disease*. Second edition. Amsterdam: Academic Press.

Chhem, R.K., & Brothwell, D.R. (2007) *Paleoradiology: Imaging Mummies and Fossils*. Springer Science & Business Media.

Čavka, M., Kelava, T., Čavka, V., Bušić, Ž., Olujić, B., & Brkljačić, B. (2010) Homocystinuria, a Possible Solution of the Akhenaten's Mystery. *Coll. Antropol.* 34 Suppl 1, 255-258.

Chapman, M., Murray, R.O., & Stoker, D.J. (1979) Tuberculosis of the Bones and Joints. *Seminars in Roentgenology* 14 (4), 266-282. [https://doi.org/10.1016/0037-198X\(79\)90024-5](https://doi.org/10.1016/0037-198X(79)90024-5)

Dupras, T.L., Williams, L.J., Willems, H., & Peeters, C. (2010) Pathological skeletal remains from ancient Egypt: the earliest case of diabetes mellitus? *Pract Diab Int* 27(8), 358-363a. <https://doi.org/10.1002/pdi.1523>

Entezami, P., Fox, D., Clapham, P., & Chung, K. (2011) Historical perspective on the etiology of rheumatoid arthritis. *Hand Clin* 27(1), 1-10. <https://doi.org/10.1016/j.hcl.2010.09.006>

Gorjanović-Kramberger, D. (1899). *Der paläolithische Mensch und seine Zeitgenossen aus dem Diluvium von Krapina in Kroatien*. *Mitteilungen der Anthropologischen Gesellschaft in Wien* 29, 65-68.

Harris, A., & Violand, M. (2022) Charcot Neuropathic Osteoarthropathy. *StatPearls* [Internet]. <https://www.ncbi.nlm.nih.gov/books/NBK470164> Accessed 29 July 2022.

Hershkovitz, I., Donoghue, H.D., Minnikin, D.E., Besra, G.S., Lee, O.Y.C., Gernaey, A.M., Galili, E., Eshed, V., Greenblatt, C.L., Lemma, E., Bar-Gal, G.K., & Spigelman, M. (2008) Detection and Molecular Characterization of 9000-Year-Old Mycobacterium tuberculosis from a Neolithic Settlement in the Eastern Mediterranean. *PLOS ONE* 3(10), e3426. <https://doi.org/10.1371/journal.pone.0003426>

King, K.M., & Rubin, G. (2003) A history of diabetes: from antiquity to discovering insulin. *Br J Nurs* 12(18), 1091–5. <https://doi.org/10.12968/bjon.2003.12.18.11775>

Lee, L., Blume, P.A., & Sumpio, B. (2003) Charcot joint disease in diabetes mellitus. *Ann Vasc Surg.* 17(5), 571–80. <https://doi.org/10.1007/s10016-003-0039-5>

- Lippi, D., Matucci-Cerinic, M., Alburyc, W.R., & Weisz, G.M. (2014) Inherited knee disorders in the Medici family. *The Knee* 21(1), 2-5. <https://doi.org/10.1016/j.knee.2013.11.006>
- Lorenzo, J., Horowitz, M., Yongwon, C., Takayanagi, H., & Schett, G. (2015) *Osteoimmunology Interactions of the Immune and Skeletal Systems*. 2nd Edition, Elsevier: Academic Press.
- Milotić, I. (2010.) Crkva u Istri, povijesna i kulturna baština. Pazin – Poreč: Porečkopulska biskupija.
- Naranjo, P. (1994) On the American Indian origin of syphilis: fallacies and errors. *Allergy Proc.* 15(2), 89–99. <https://doi.org/10.2500/108854194778703044>
- Nicklisch, N., Maixner, F., Ganslmeier, R., Friederich, S., Dresely, V., Meller, V., Zink, A., & Alt, K.W. (2012) Rib lesions in skeletons from early neolithic sites in Central Germany: On the trail of tuberculosis at the onset of agriculture. *Am J Phys Anthropol* 149, 391-404. <https://doi.org/10.1002/ajpa.22137>
- Notman, D.N., Anderson, L., Beattie, O., & Amy, R. (1987). Arctic paleoradiology: portable radiographic examination of two frozen sailors from the Franklin expedition (1845-1848). *AJR Am J Roentgenol.* 149(2), 347-50. <https://doi.org/10.2214/ajr.149.2.347>
- Ortner, D.J. (2003) *Identification of pathological conditions in human skeletal remains*. Second edition. San Diego, CA: Academic Press.
- Parvizi, J., Marrs, J., & Morrey, B.F. (2003) Total knee arthroplasty for neuropathic (Charcot) joints. *Clin Orthop Relat Res.* 416, 145–50. <https://doi.org/10.1097/01.blo.0000081937.75404.ed>
- Pinzur, M.S. (2000) Charcot's foot. *Foot Ankle Clin* 5(4), 897-912.
- Redfern, R.C., & Austin, A. (2020) Ankylosis of a knee joint from Medieval London: Trauma, congenital anomaly or osteoarthritis? *Int J Paleopathol* 28, 69-87. <https://doi.org/10.1016/j.ijpp.2019.10.002>
- Rietschel, E.T., Rietschel, M., & Beutler, B. (2004) How the mighty have fallen: fatal infectious diseases of divine composers. *Infect Dis Clin North Am* 18(2), 311–339. <https://doi.org/10.1016/j.idc.2004.02.002>
- Roberts, C.A., & Manchester, K. (2010) *The archaeology of disease*. Third edition. Stroud: The History Press.
- Rogers, L.C., Frykberg, R.G., Armstrong, D.G., Boulton, A.J., Edmonds, M., Van, G.H., Hartemann, A., Game, F., Jeffcoate, W., Jirkovska, A., Jude, E., Morbach, S., Morrison, W.B., Pinzur, M., Pitocco, D., Sanders, L., Wukich, D. K., & Uccioli, L. (2011) The Charcot Foot in Diabetes. *Diabetes Care* 34(9), 2123-2129. <https://doi.org/10.2337/dc11-0844>
- Rühli, F.J., Chhem, R.K., & Böni, T. (2004). Diagnostic paleoradiology of mummified tissues: interpretation and pitfalls. *Can Assoc Radiol J.* 55, 218-227.
- Rühli, F.J., Galassi, F.M., & Haeusler, M. (2016) Palaeopathology: Current challenges and medical impact. *Clin Anat.* 29(7), 816-22. <https://doi.org/10.1002/ca.22709>
- Sella, E.J., & Barrette, C. (1999) Staging of Charcot neuroarthropathy along the medial column of the foot in the diabetic patient. *J Foot Ankle Surg.* 38(1) 34–40. [https://doi.org/10.1016/S1067-2516\(99\)80086-6](https://doi.org/10.1016/S1067-2516(99)80086-6)
- Sparks, J.A. (2019) Rheumatoid Arthritis. *Annals of Internal Medicine* 170(1), ITC1-ITC16. <https://doi.org/10.7326/AITC201901010>
- Zesch, S., Panzer, S., Rosendahl, W., Nance, J.W. Jr, Schönberg, S.O., & Henzler, T. (2016) From first to latest imaging technology: Revisiting the first mummy investigated with X-ray in 1896 by using dual-source computed tomography. *Eur J Radiol Open.* 3, 172-181. <https://doi.org/10.1016/j.ejro.2016.07.002>